

Advances in Hip and Knee Surgery Club Continental

Dr Max Lincoln, FRCSC
Southeast Orthopedic Specialists
April 9, 2019

Dr Max Lincoln, MD

Medical Degree

Queen's University School of Medicine, Kingston, ON

Orthopedic Surgery Residency

University of Calgary Foothills Medical Centre, Calgary, AB

Adult Reconstructive Surgery and Trauma Fellowship

Mount Sinai Hospital, Sunnybrook Health Sciences Centre, Toronto, ON

Adult Reconstructive Surgery Fellowship

Sharp Memorial Hospital, San Diego, CA

Certification

Board-Certified Fellow, Royal College of Physicians and Surgeons of Canada

Professional Affiliation

Licentiate, Medical Council of Canada

American Association of Hip and Knee Surgeons

American Medical Association



Max Lincoln, MD

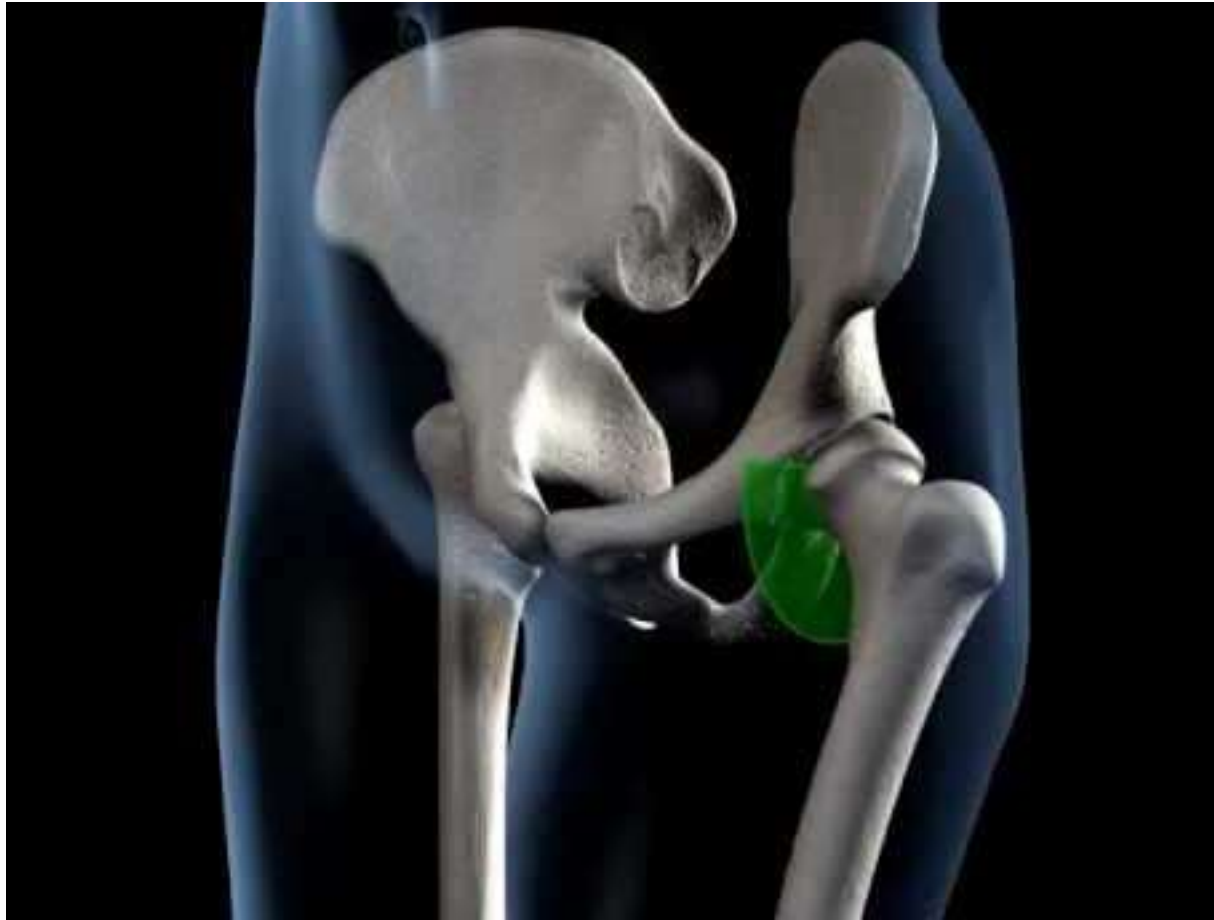Disclosure

- Stryker Orthopaedics, Clinical Research support

Advances in Hip surgery

Balancing short term benefits with long term outcomes

The Noble Hip Joint



The C-Sign of the Hip

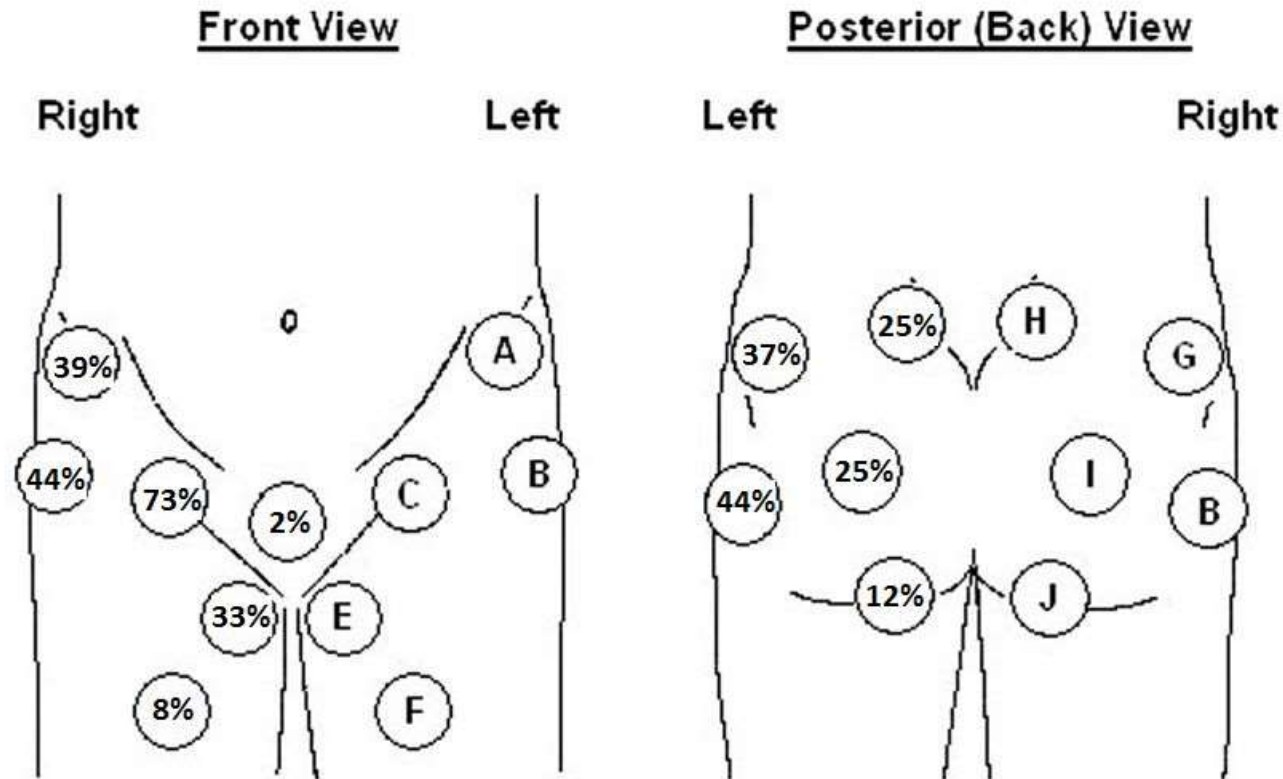
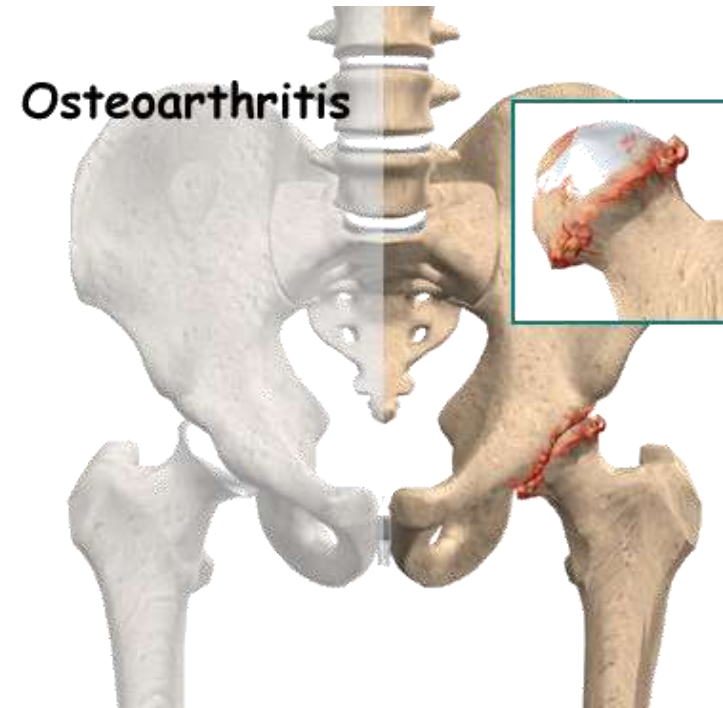


Figure 1. The new pain "circle" diagram developed for this study had circles in which patients put an "X" to indicate pain in the following areas: A) anterior superior spine; B) lateral peritrochanteric area; C) central groin; D) symphysis pubis; E) proximal inner thigh; F) anterior thigh; G) posterior iliac crest; H) sacroiliac joint; I) sciatic notch; and J) ischial tuberosity. The circles are placed over anatomic locations commonly associated with hip pain.

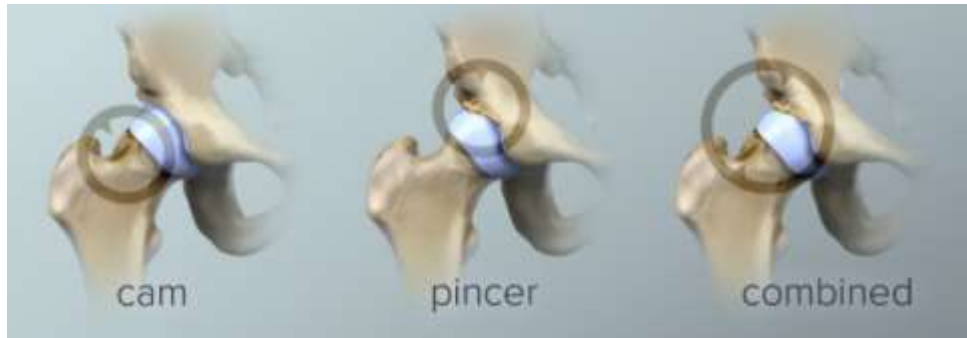Osteoarthritis

Osteoarthritis (OA) is a degenerative joint disease in which the cartilage covering the ends of the bones deteriorates.

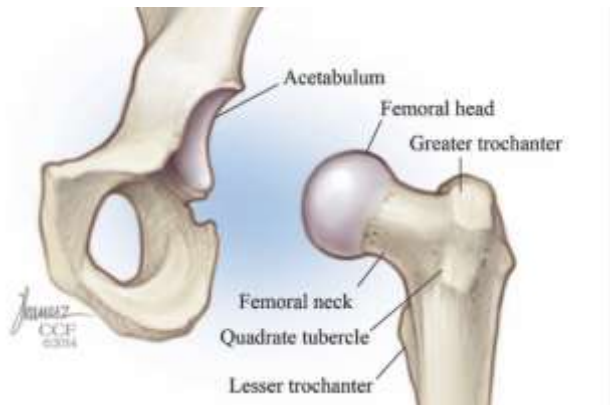
- Most common form of arthritis
- Affects 31M Americans
 - Almost 2/3 are Working Age
- Contributing factors:
 - Advanced age
 - Weight
 - Lack of exercise
 - Previous injury
- Cause in hip may relate to morphology of ball and socket articulation



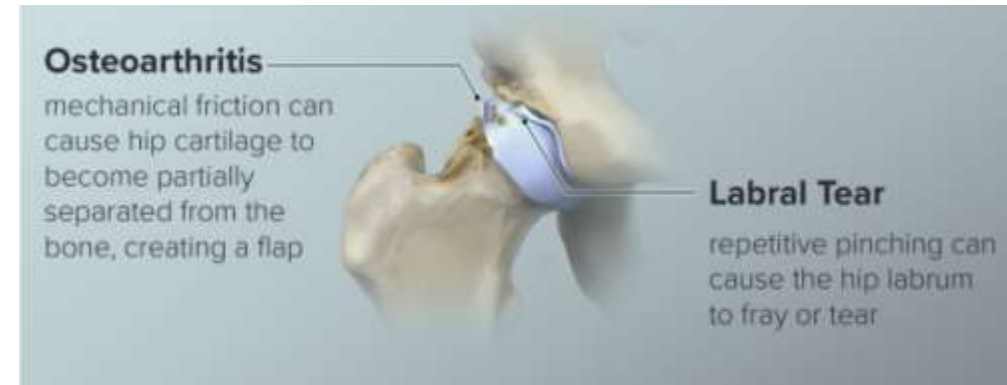
Hip Osteoarthritis is a “Coverage Issue”



TOO MUCH



TOO LITTLE



Non-Surgical Treatments for Hip Osteoarthritis

- Education
- Modification of physical activity
- PT to increase strength, improve flexibility and gait pattern
- Weight reduction
- NSAIDS/Acetaminophen if candidate
- Injections
 - Cortisone (FDA approved)
 - Hyaluronic Acid
 - Regenerative Therapy (PRP, Stem Cell)



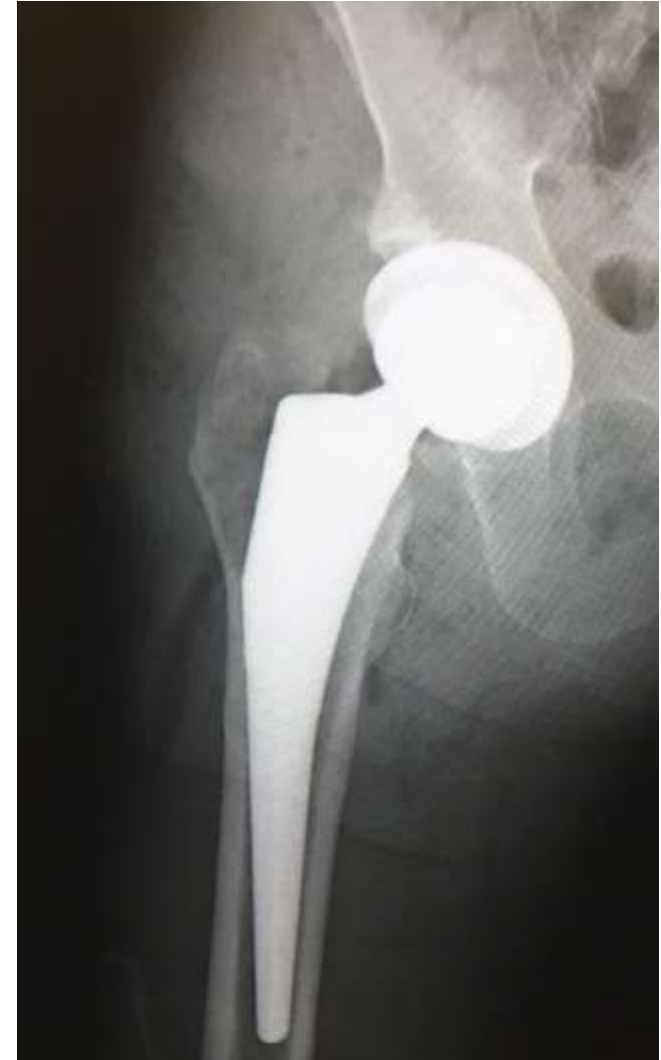Enter the Total Hip Replacement...

Total Hip Replacement


- “the operation of the 20th century”
- More than 1 M implanted worldwide annually
- 2.5 million living in the US today
- Aging demographic driving up number of implants
- Treatment option more prevalent for younger patients (40s-50s)
- Survival 25 years, 80%
- Patient satisfaction scores >93%

**Millennium Research Group Report, 2005*


**www.arthritistoday.org/news/americans-with-artificial-joints-337.php, 2014*



Evolution of Total Hip Arthroplasty



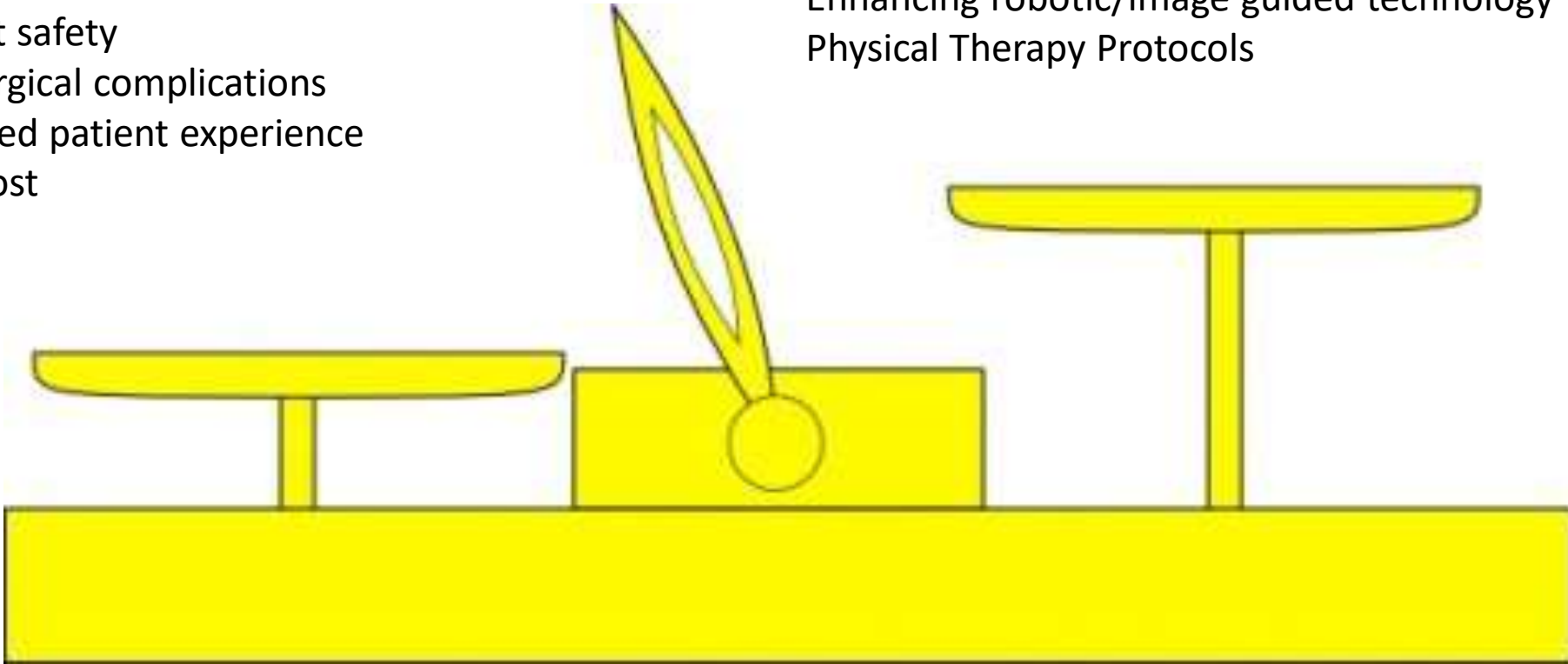
IMPLANTS
BEARING SURFACES
SURGICAL TECHNIQUES
BLOOD LOSS MANAGEMENT
ADJUNCT TECHNOLOGIES
PHYSICAL THERAPY PROTOCOLS
ANALGESIA



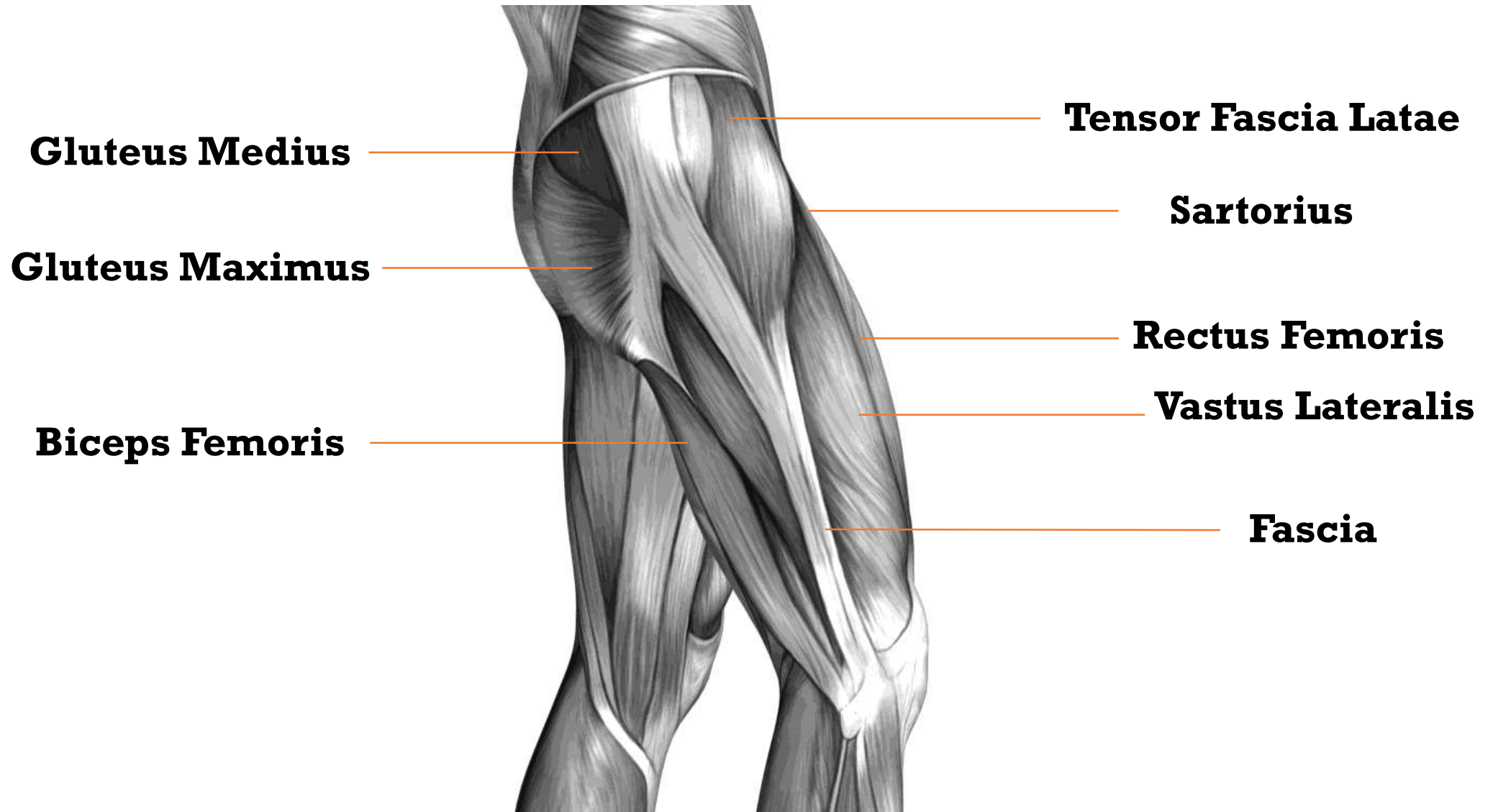
The Problem

Long Term Outcomes
Implant safety
Low surgical complications
Improved patient experience
Low Cost

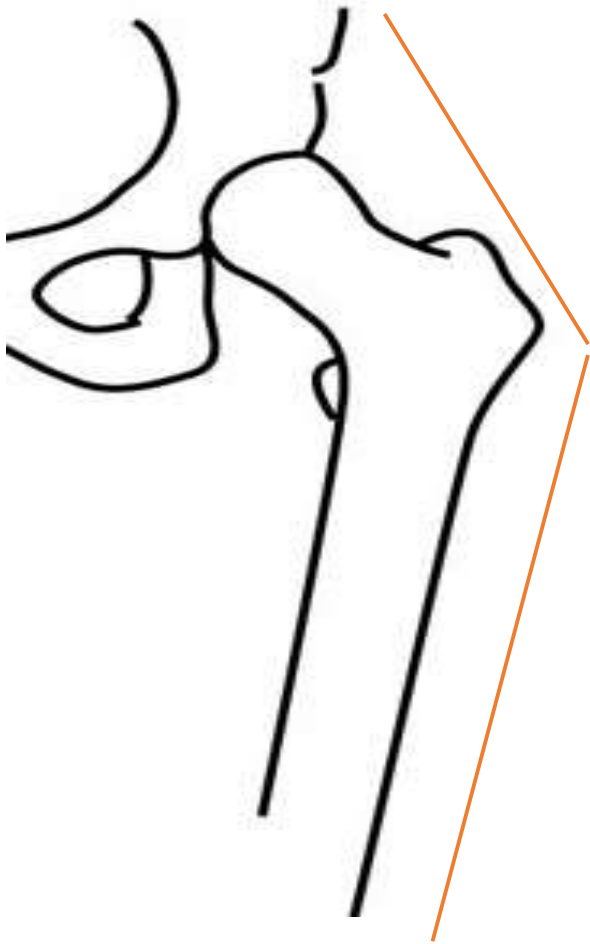Implant Technologies (3D Printing, Polyethylene, shorter stems)
Low wear bearing surface
Tendon sparing surgical approaches
Enhancing robotic/image guided technology
Physical Therapy Protocols



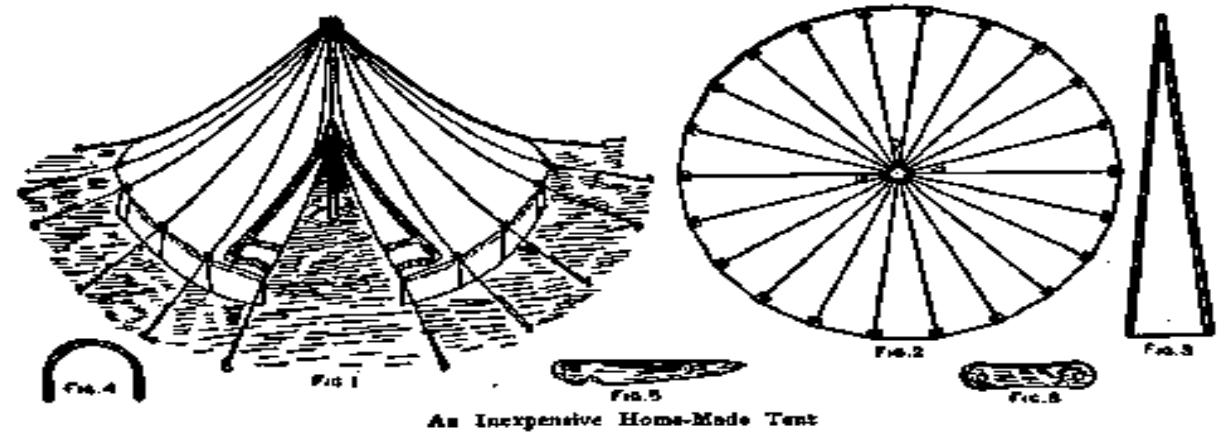
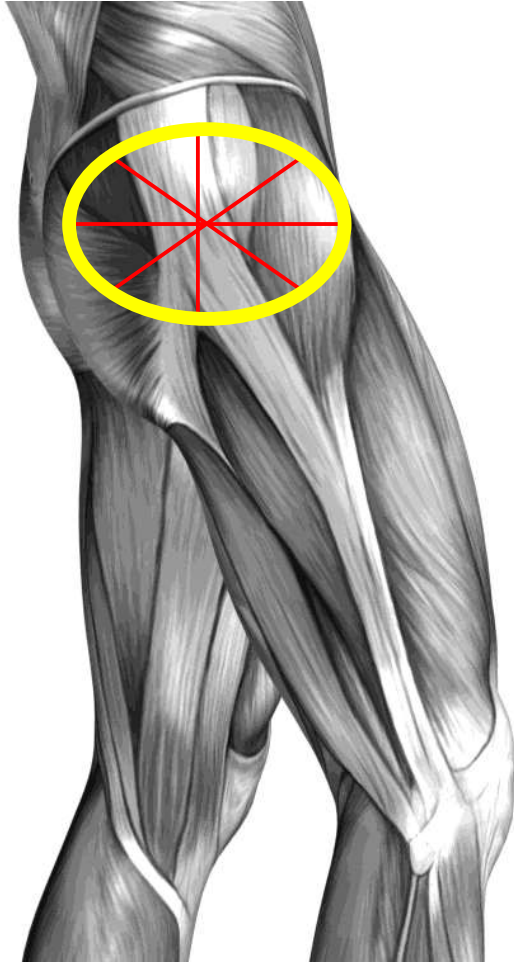
Surgical Approaches to the Hip



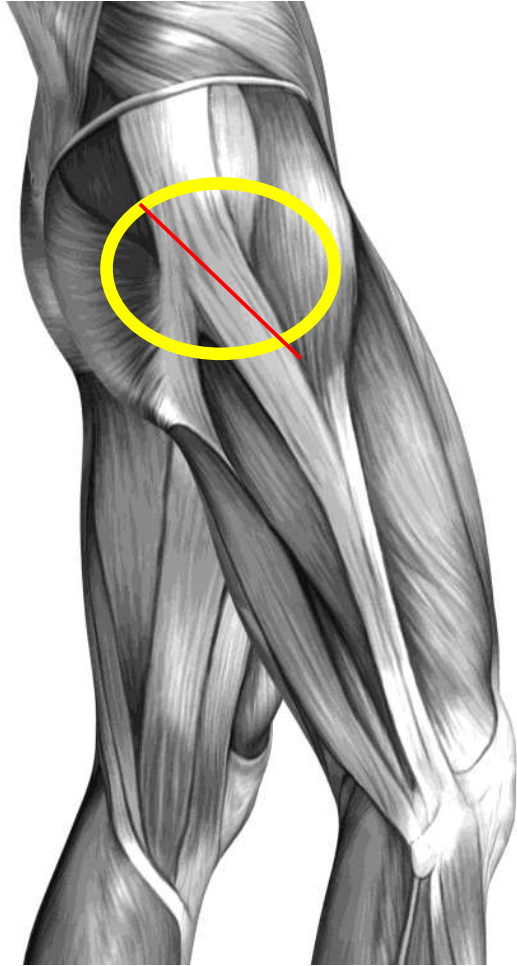
Iliotibial Band



Iliotibial Band



Iliotibial Band in Posterior Approach

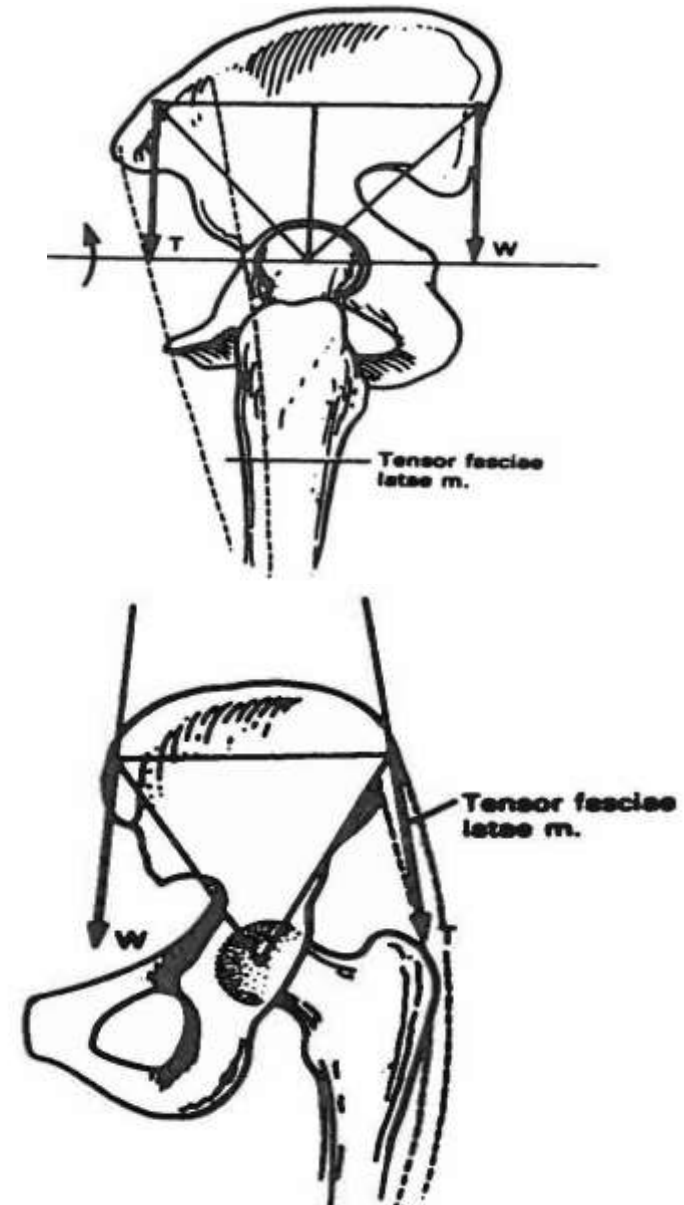


Importance of the IT Band (aka Tensor Fascia Lata)

Gottschalk F, Kourosh S, Leveau B. The Functional anatomy of tensor fascia latae and gluteus medius and minimus. J Anatomy 1989

- 11 cadavers dissected
- Shape and orientation of abductor muscles defined
- EMG of tensor fascia latae in 10 normal subjects during gait cycle and isolated abduction of the lower limb

Summary: The IT Band is the main hip abductor and holds the pelvis level during stance



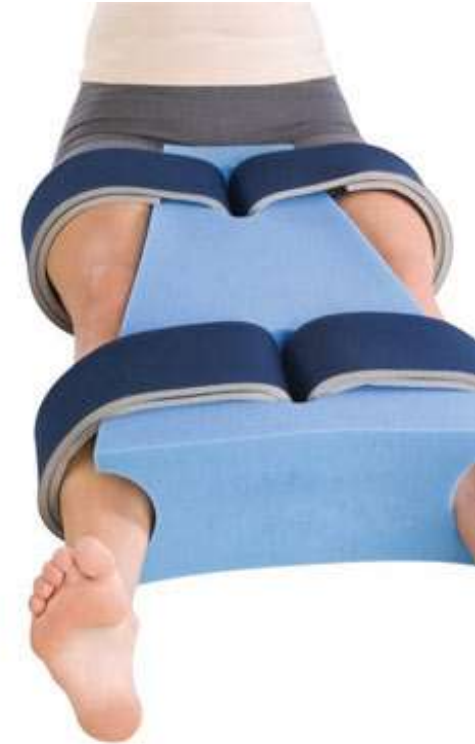Concerns with Posterior Approach THR


Short Term

- Pain (longer LOS, Narcotics)
- Blood loss (transfusion, drainage)
- Rigid posterior hip precautions

Long Term

- Altered Gait (limb lengthening, bursitis)
- Bearing Surface (large heads)

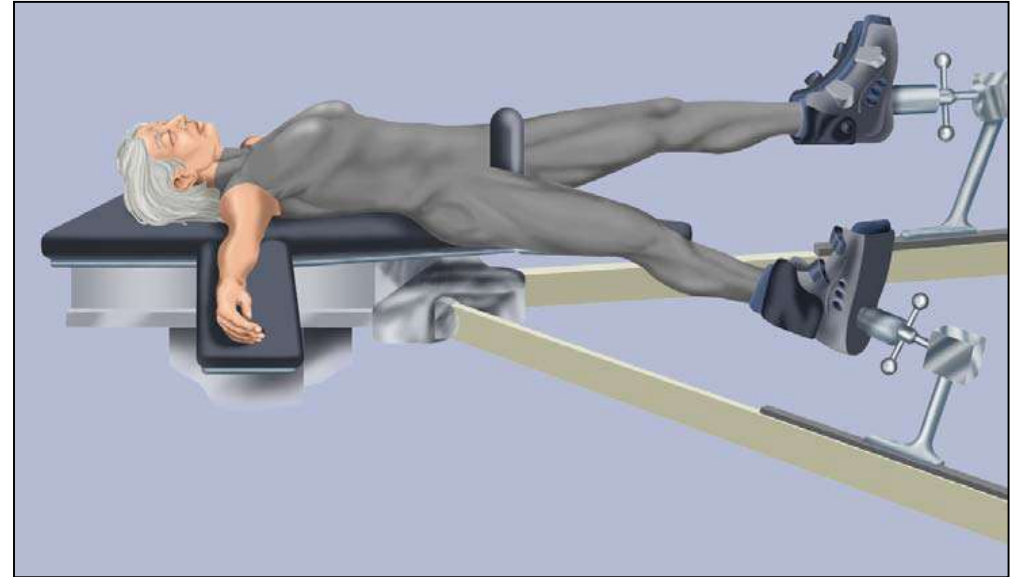
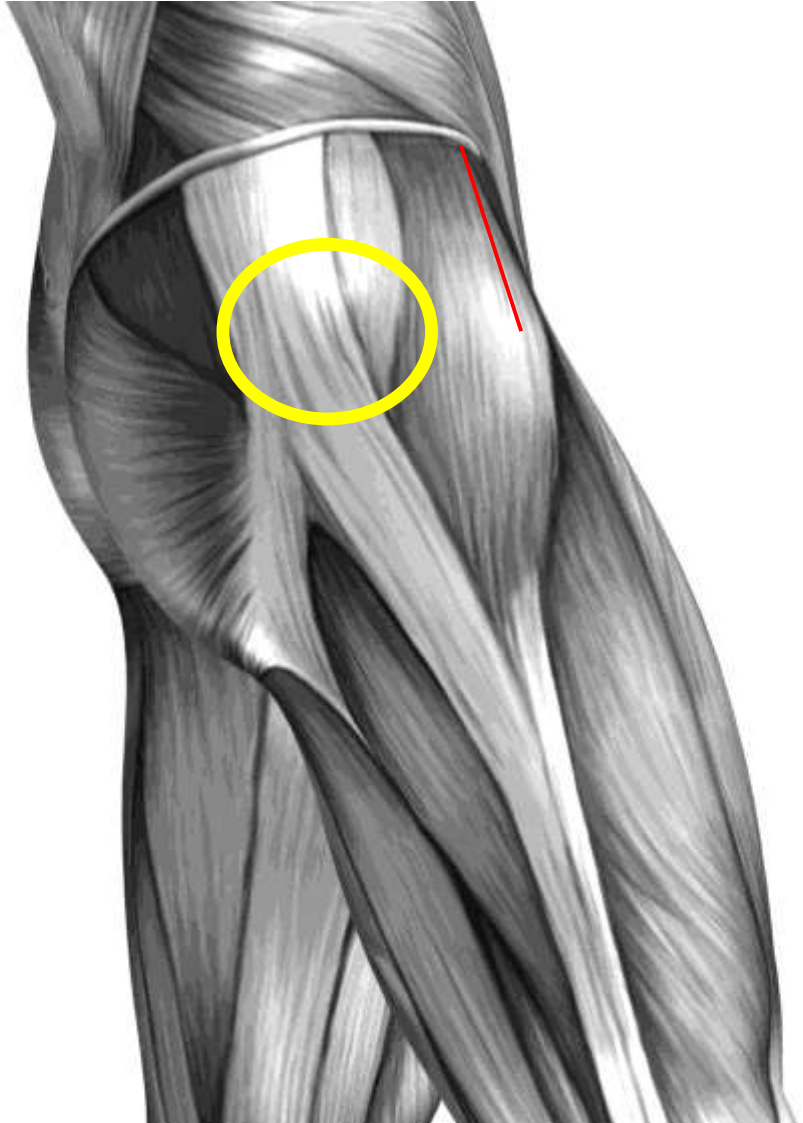


A landscape photograph showing a road that splits into two paths, each leading through a field of tall, golden-brown grain. The sky is filled with dramatic, dark clouds, and the sun is low on the horizon, creating a warm, golden light. The overall scene is peaceful and evocative.

Direct Anterior (DA)

Direct Superior (DS)

Direct Anterior



DA Hips: What's Good, What's Bad

What's Good

- IT Band Sparing
- Less dislocation risk
- Intraoperative Xray
- Early recovery
- Marketing

What's Bad

- Risk of femur fracture and early femoral component loosening
- Blood Loss
- LFCN palsy
- Rectus Femoris Tendinopathy
- Cannot be used for revision
- Wound breakdown

And...



Greater inadvertent muscle damage in direct anterior approach when compared with the direct superior approach for total hip arthroplasty

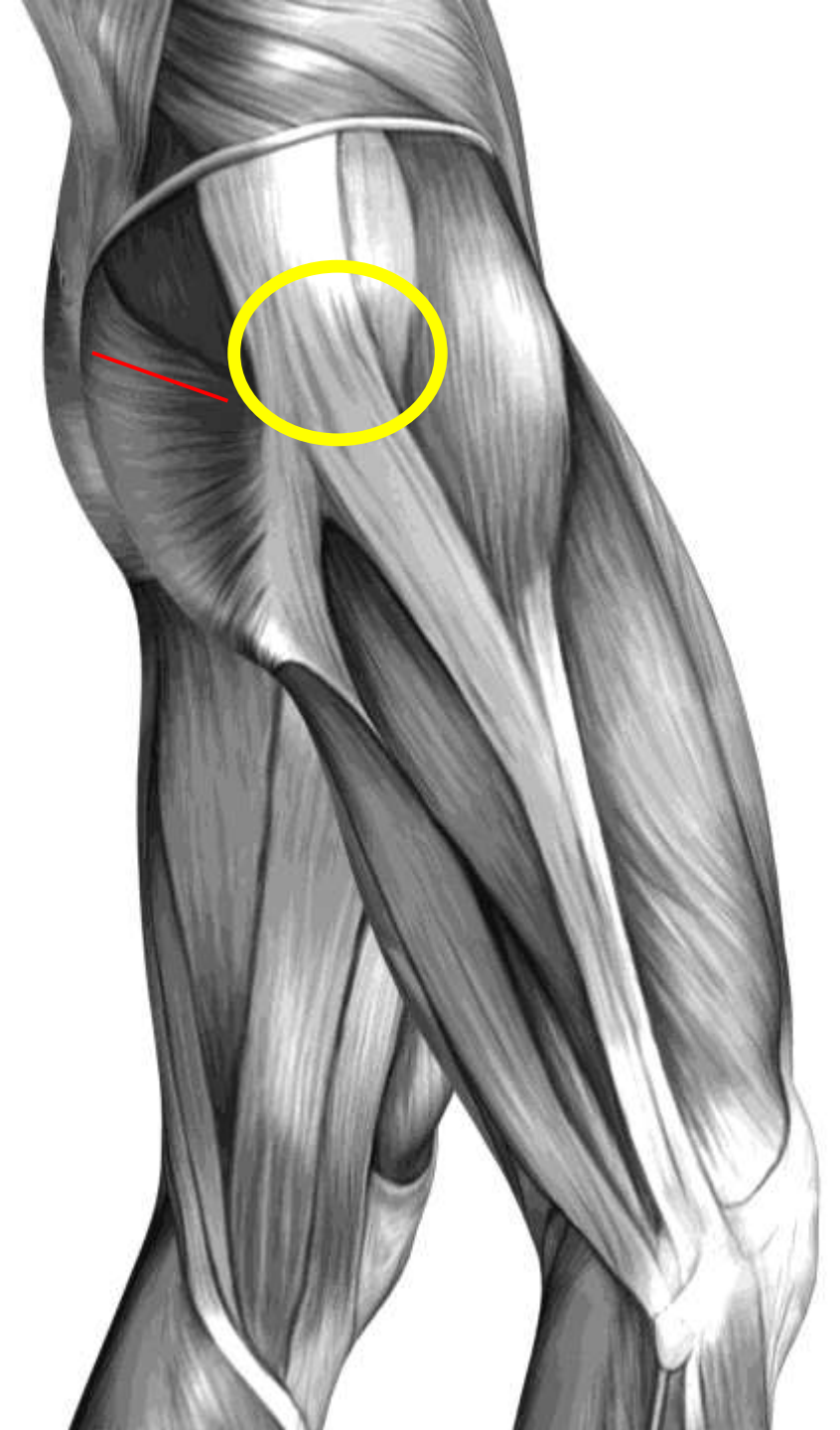
D. F. Amanatullah, M. A. Masini, D. J. Roger, M. W. Pagnano

Aims We wished to quantify the extent of soft-tissue damage sustained during minimally invasive total hip arthroplasty through the direct anterior (DA) and direct superior (DS) approaches.

Materials and Methods In eight cadavers, the DA approach was performed on one side, and the DS approach on the other, a single brand of uncemented hip prosthesis was implanted by two surgeons, considered expert in their surgical approaches. Subsequent reflection of the gluteus maximus allowed the extent of muscle and tendon damage to be measured and the percentage damage to each anatomical structure to be calculated.

Results The DA approach caused substantially greater damage to the gluteus minimus muscle and tendon when compared with the DS approach (*t*-test, $p = 0.049$ and 0.003 , respectively). The tensor fascia lata and rectus femoris muscles were damaged only in the DA approach. There was no difference in the amount of damage to the gluteus medius muscle and tendon, piriformis tendon, obturator internus tendon, obturator externus tendon or quadratus femoris muscle between approaches. The posterior soft-tissue releases of the DA approach damaged the gluteus minimus muscle and tendon, piriformis tendon and obturator internus tendon.

So what is Direct Superior?



Direct Superior Surgical Approach

- IT Band Sparing approach via Gluteus Maximus
- Acetabular component prepared with percutaneous canula (SuperPATH) with complete tendon sparing
- Robotically enhanced technology utilizes additional SER release
- Extensile for revision surgery

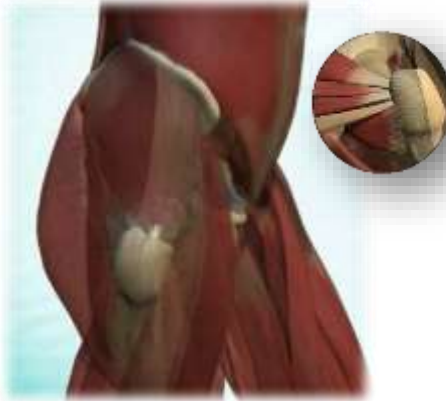

Why the Direct Superior Hip Technique?

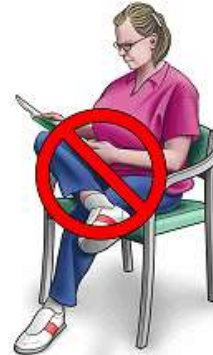(from a patients perspective)

It's possible to walk within hours of surgery.

- Fast Hospital Recovery¹
- Muscle-preserving technique
- No typical hip bending restrictions



Do not bend your operated hip beyond a 90° angle.



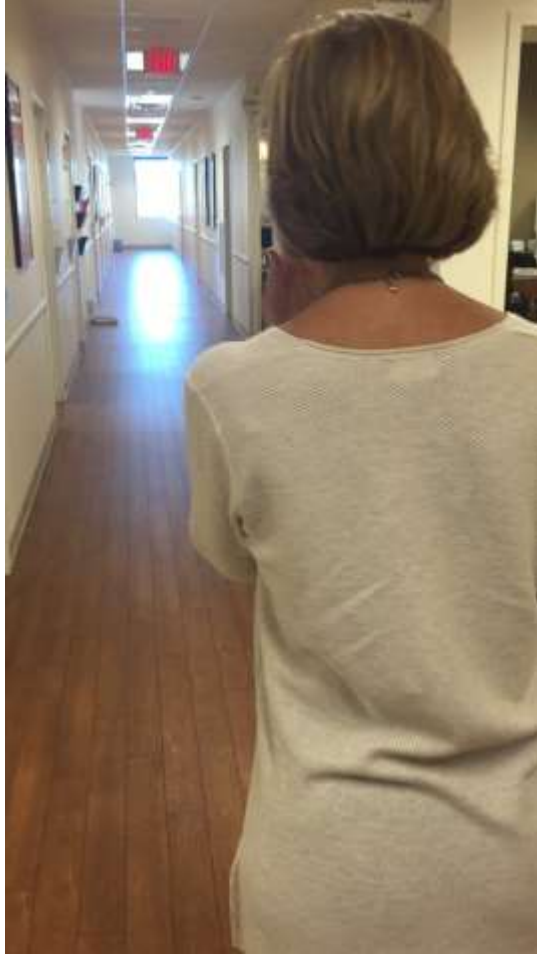Do not cross your operated leg or ankle.



Do not turn your operated leg inward in a pigeon-toed position.

¹ Chow J, Penenberg B, Murphy S. Modified Micro-Superior Percutaneously-Assisted Total Hip: Early Experiences & Case Reports. *Curr Rev Musculoskelet Med* (2011) 4:146-150

Enhanced Early Recovery

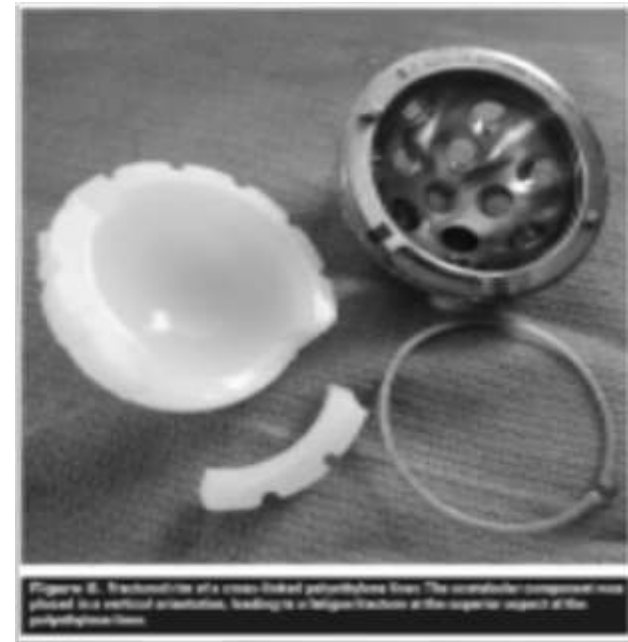

How can new technologies improve traditional results?

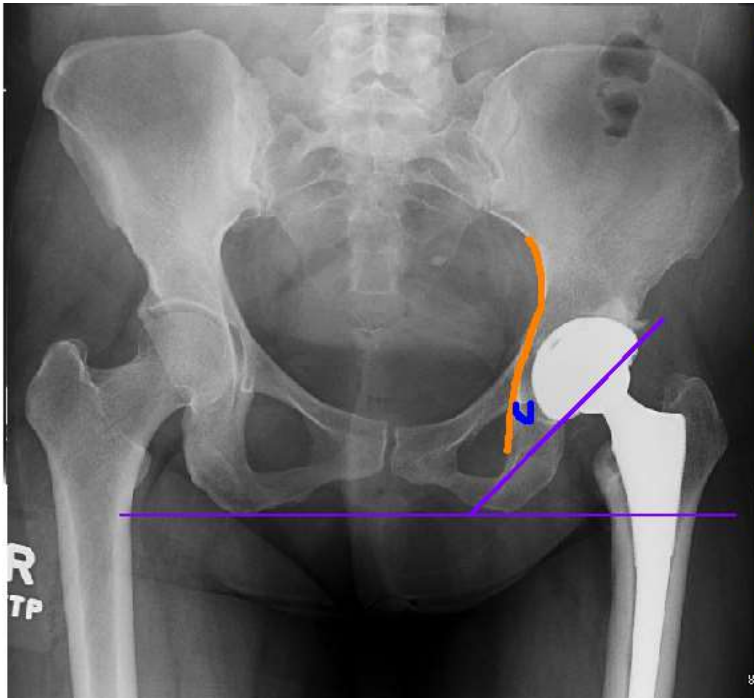
1. Component Malpositioning

- Dislocation
- Impingement
- Component wear

2. Facilitate MIS Surgery



Component position: Do we hit the target?



INCLINATION

- angle between 2 lines
1. horizontal reference
(line across ischial tuberosities)
 2. line across rim of cup

DEPTH

- cup should sit up against
the ilio-ischial line for
appropriate depth

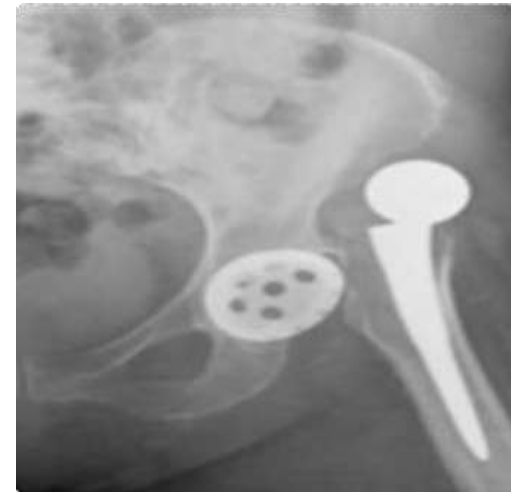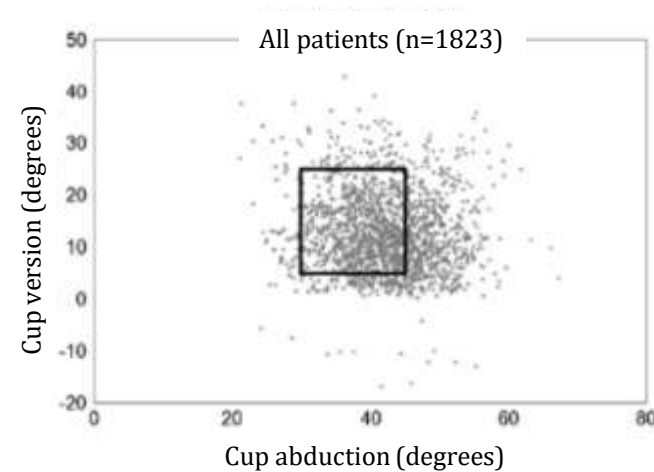
HEIGHT

- inferior aspect of cup
should sit at the tear drop.
use contralateral side as a
reference



Traditional Methods of Component Placement

- Clinical study - Massachusetts General Hospital
- 1,823 hips
- Acceptable cup placement:
 - Inclination: 30-45°
 - Anteversion: 5-25°
- Study found that the acetabular cup was placed in the acceptable safe range only 50% of the time.



Outcomes after primary total hip arthroplasty: manual compared with Robotic-Assisted Techniques²⁸⁻³¹

- **Principal investigators**

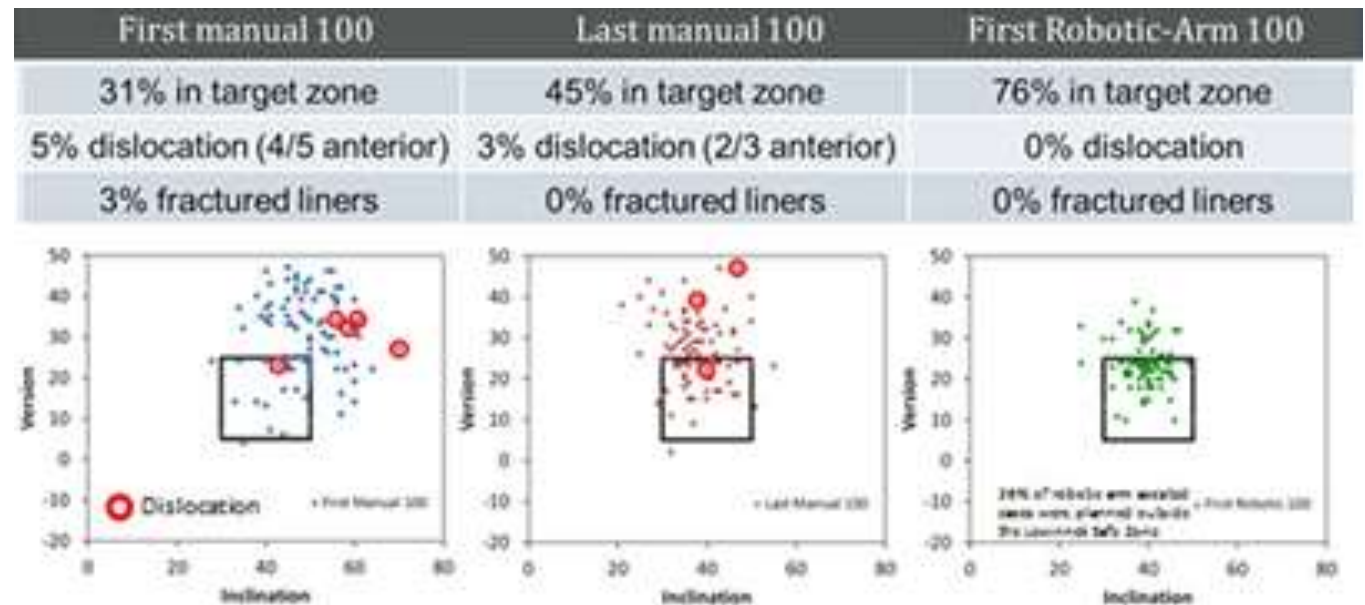
- Richard Illgen, MD

- **Methodology**

- 1st 100 consecutive manual THA cases (2000)
- Last 100 consecutive manual THA cases (2011)
- 1st 100 consecutive robotic-arm assisted (rTHA) THA cases (2012)
- Radiographic and clinical outcomes assessment

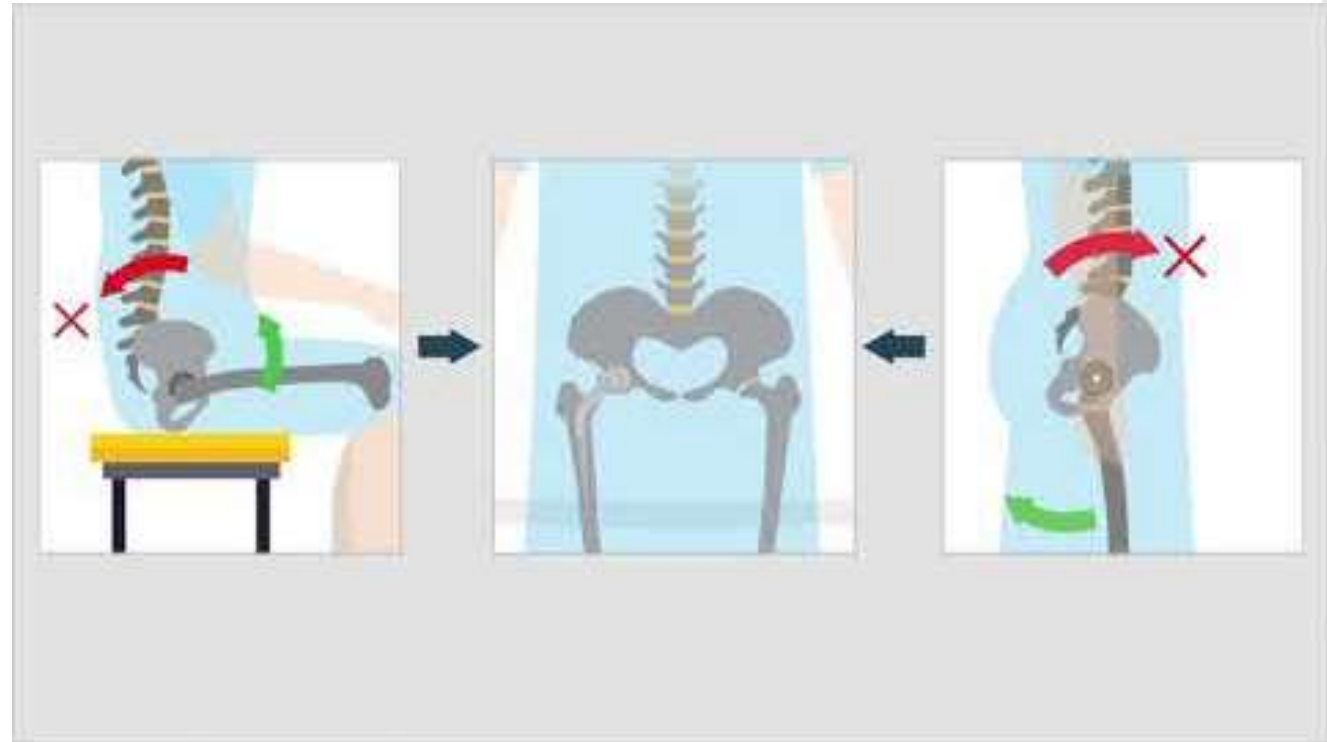
- **Results**

- Robotic-arm assisted THA demonstrated significantly higher modified Harris Hip Score and UCLA activity level compared with manual THA at a minimum 1 year follow up.
- Estimated blood loss was reduced in the rTHA patients.
- The average error (final placement compared to planned placement) was $-0.7 \pm 2.1^\circ$ for inclination and $1.1 \pm 2.0^\circ$ for version. 93% of the inclination measurements and 94% of the version measurements were within 5° of the plan and 100% of both measurements were within 10° of the plan.

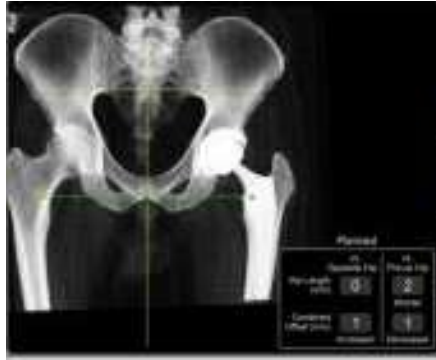

Effect of Spine on Component Position

- Pelvic Tilt dynamically changes Acetabular Position
- **No “single target”**
- Robotic and image enhanced techniques useful
- Occasional Dual Mobility bearing



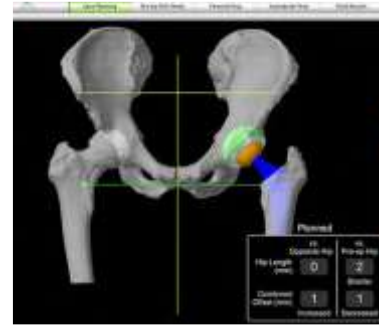
Clinical Advantage of Robotics in THA



Enhanced planning

Patient-specific pre-operative plan enables more accurate implant positioning.⁷⁻¹¹ CT data is segmented to create a 3D model of the patient's bony anatomy.

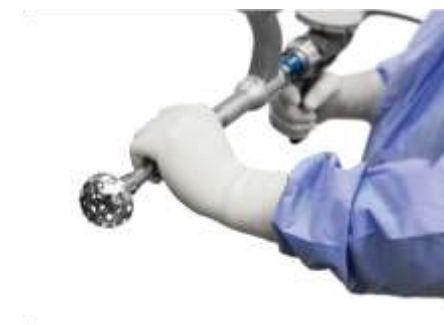An individualized pre-operative plan is created and reviewed with the surgeon prior to the Mako procedure.



Dynamic joint balancing

Surgeon-controlled intra-operative adjustments can be made to optimize implant placement.¹² Kinematic and soft tissue data are collected intraoperatively and applied to the virtual CT model.

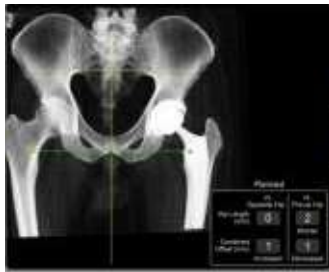The surgeon reviews the pre-op plan and can modify it if necessary based on the intra-operative data to virtually balance the joint and achieve individualized placement.



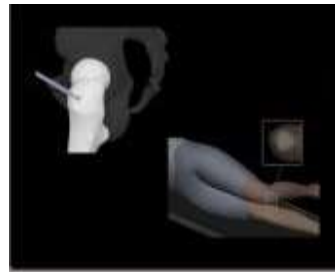
Robotic-arm assisted bone preparation

The surgeon then executes the individualized intra-operative plan using robotic-arm assisted bone preparation to achieve functional implant positioning.

Mako Total Hip



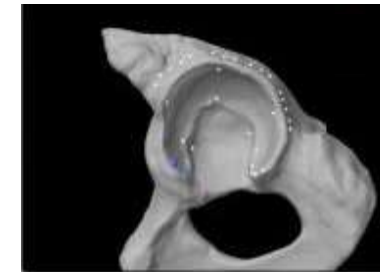
Planning



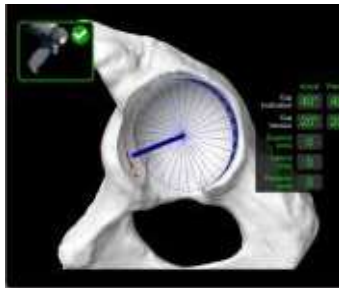
Landmark placement



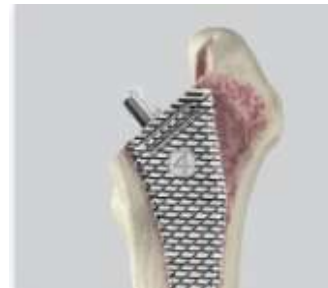Pelvic array



Verify checkpoints /
acetabular registration



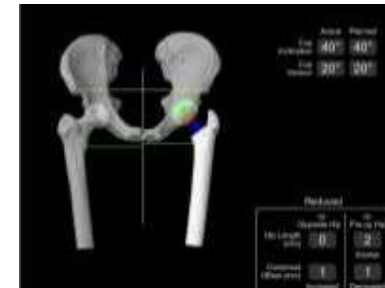
Reaming/
cup impaction



Femoral
preparation

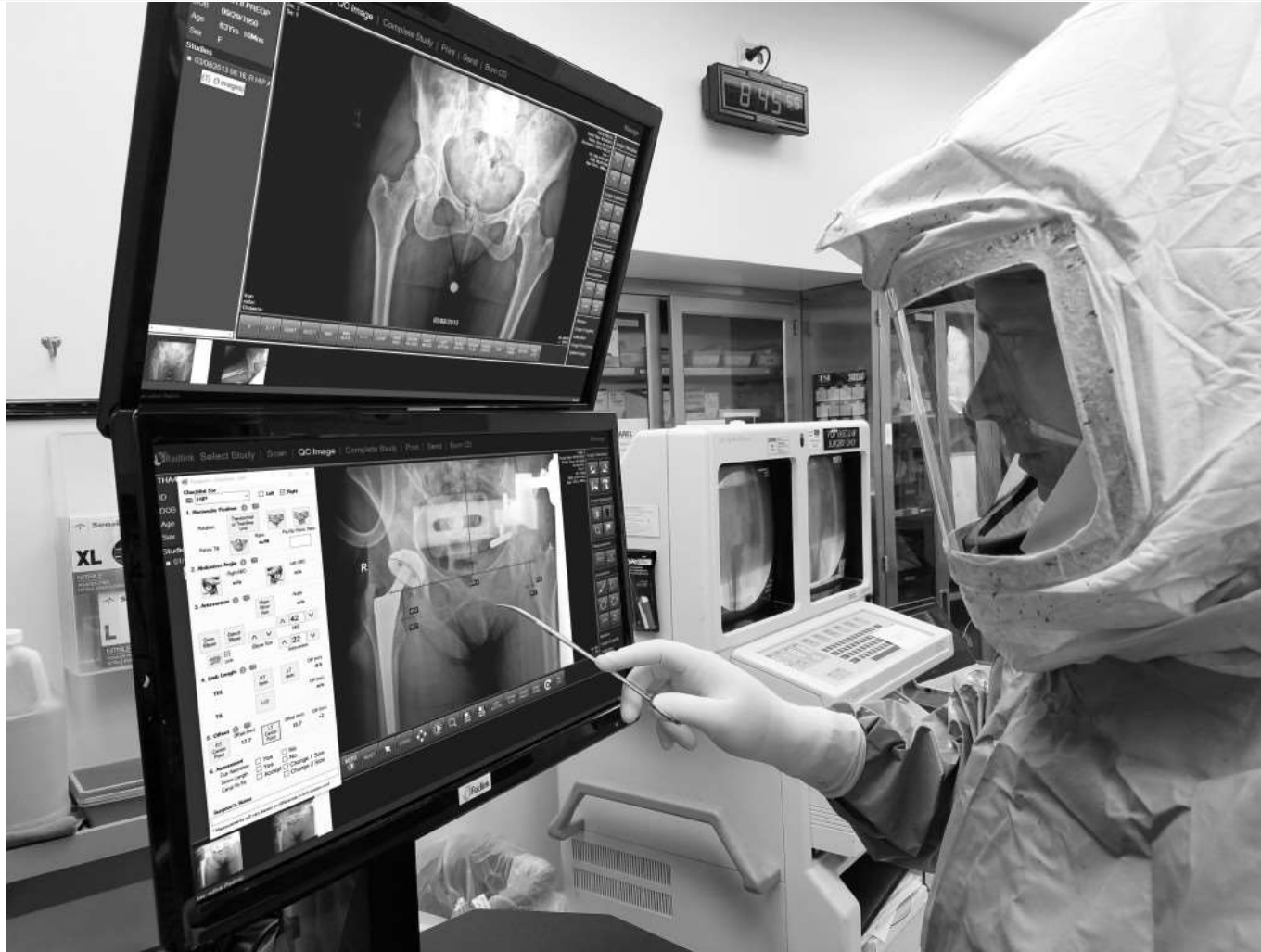

Trial
reduction



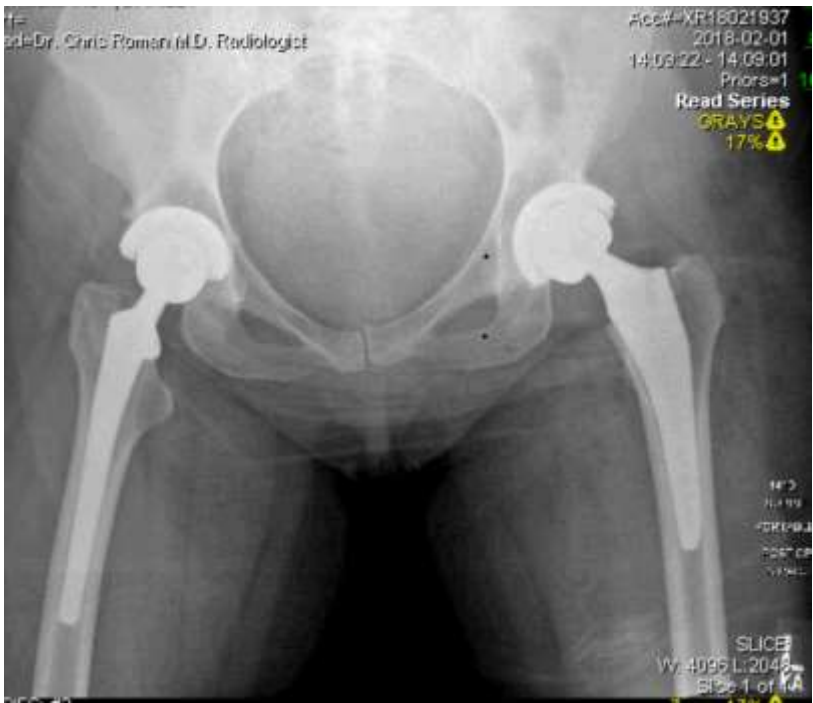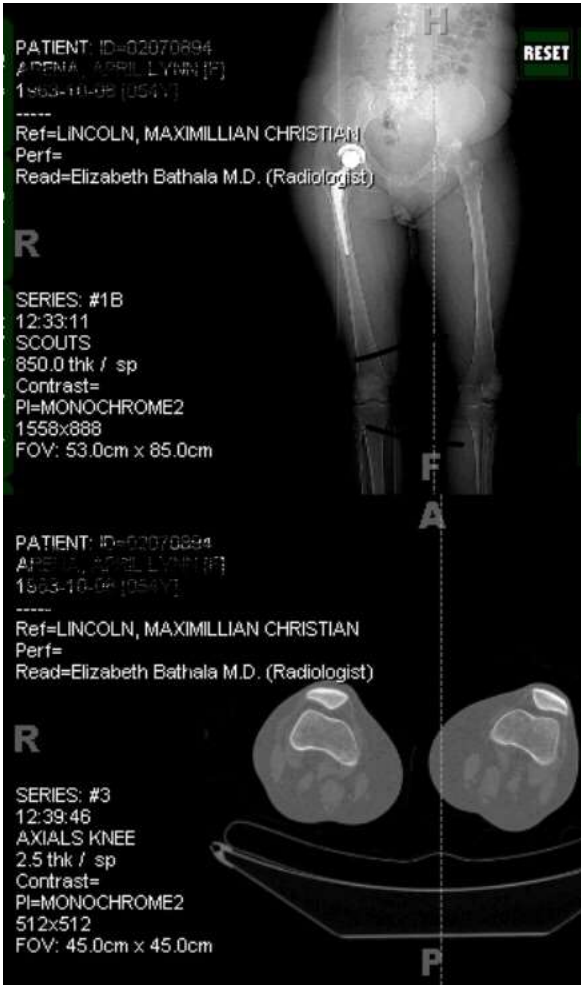
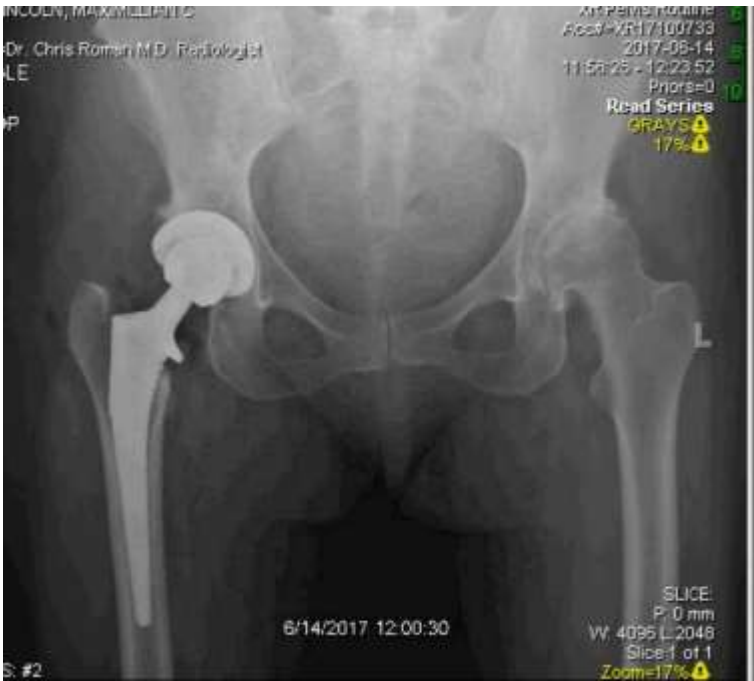Reduction results

Alternative Technologies for THA Component Placement



- Software enhanced Digital Radiography
- Shown to have high degree of accuracy with component placement
- Useful in restoration of limb length and offset
- Cost effective

Patient AA



Ensuring Success in Recovery from THA

Pre-operative medical optimization and education

- Screening malnourishment, DM, nicotine, morbid obesity and other medical issues
- Discussion of home support, work and preoperative PT

Spinal anesthesia and preoperative hydration protocols

- Diminished nausea
- Improved postoperative pain control

Intra-operative Blood Loss Management

- Tranexamic acid and hypotensive analgesia

Use of multimodal oral pain regimen

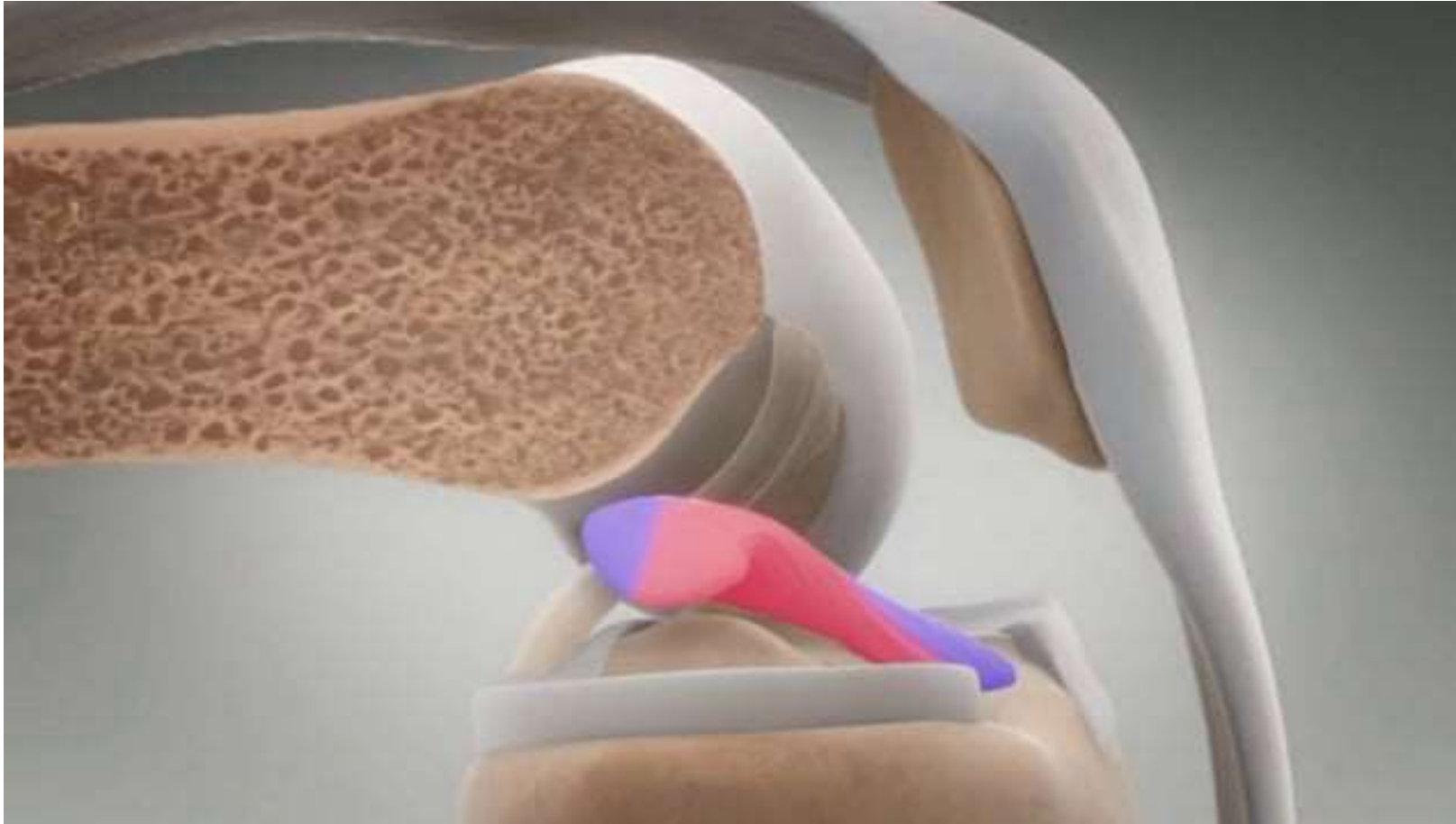
The Future of Total Hip Replacement

- IT Band Sparing Techniques
- Leveraging new technologies to improve long term outcomes
- Improved cost effectiveness

Advances in Knee surgery

Balancing short term benefits with long term outcomes

Knee Kinematics



The Knee is a Complex Joint

- Flexion (Femoral Rollback) driven by PCL, Tibia Internally rotates
 - Medial side moves 2mm posteriorly
 - Lateral side moves 21 mm posteriorly
- Extension (Screw Home) Tibia Externally Rotates, locking knee
 - Pivot around medial axis

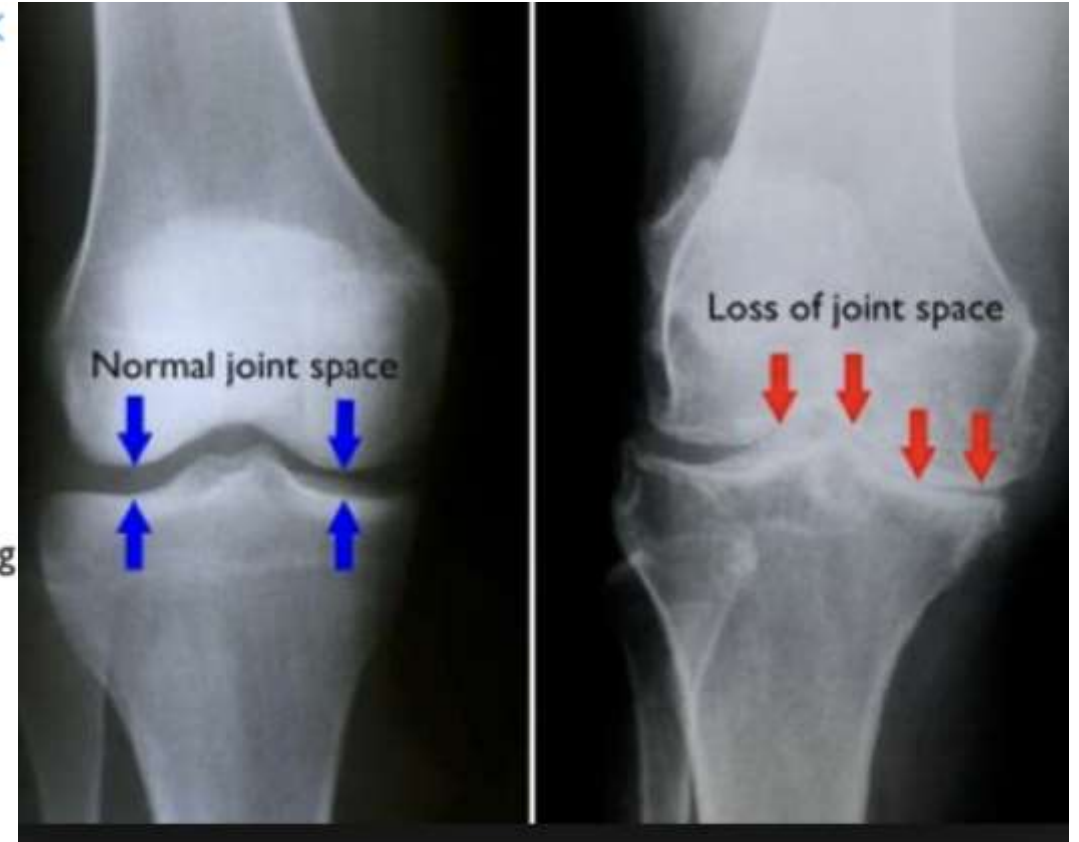
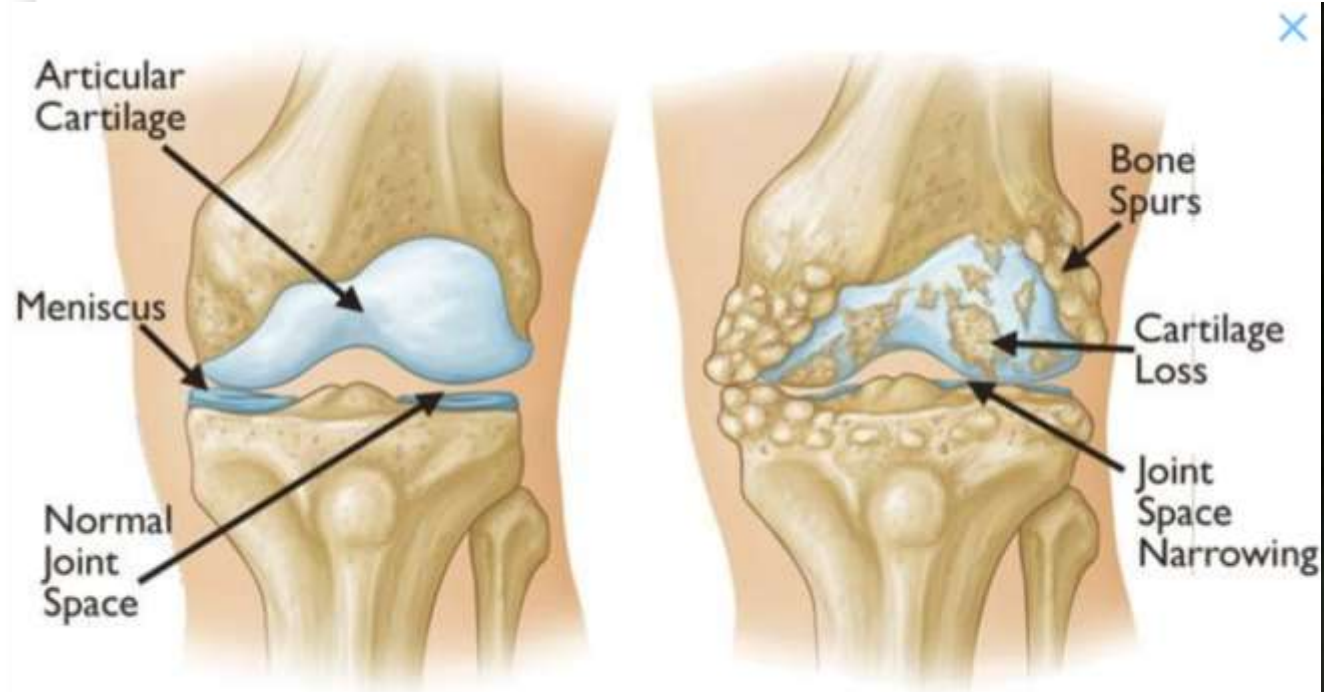
Knee Osteoarthritis- How Does it Happen?

- **We don't know!**

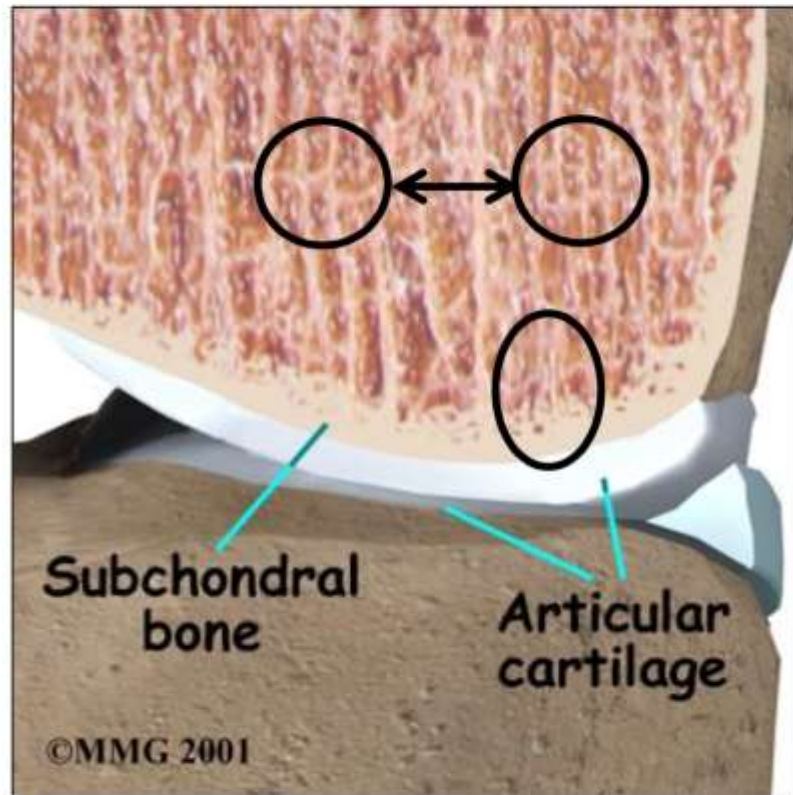
- **Associations:**

- Knee Trauma (Meniscal surgery)
- Age > 55
- Females
- Obesity (Mechanical factors, Inflammatory Mediators)
- Low Bone Density
- Muscle weakness

The Arthritic Knee















What is the Role of Subchondral Bone in Knee OA?



Healthy Subchondral Bone:

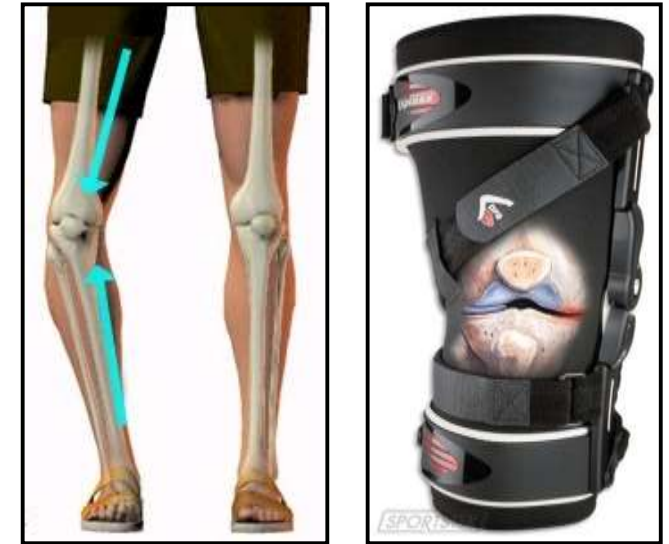- Provides support for cartilage
- Distributes joint loads vertically & horizontally

The arthritic knee

Early stage knee pain	Mid-stage OA				Late-stage OA
					
	Treatment				
<p>Knee arthroscopy</p> 	<p>Unicompartmental knee replacement</p>  <p>Medial</p>	<p>Unicompartmental knee replacement</p>  <p>Lateral</p>	<p>Patellofemoral knee replacement</p> 	<p>Medial Bicompartamental knee replacement</p> 	<p>Total knee replacement</p> 

Conservative Treatment of Knee OA

- **Low Impact Aerobic Exercise**
- **Weight Loss**
- **Medication (NSAIDs, Tramadol, Acetaminophen)**
- **Injections**
 - Cortisone
 - Viscosupplements (controversial, FDA approved)
 - Regenerative Therapy?
- **Unloading Brace**



Stem Cell Compared to HA

- **Treatment of Knee Osteoarthritis With Allogeneic Bone Marrow Mesenchymal Stem Cells: A Randomized Controlled Trial.** Vega et al Transplantation. 2015 Mar 27.
- **Methods:** 30 patients with knee OA , non responsive to “conservative measures.”
 - Bone Marrow derived MSC injection vs HA (single injection)
- **Outcomes:**
 - The MSC-treated patients displayed significant **improvement** in algofunctional indices versus the active controls treated with hyaluronic acid. Quantification of cartilage quality by T2 relaxation measurements showed a significant **decrease in poor cartilage areas**, with cartilage quality improvements in MSC-treated patients.

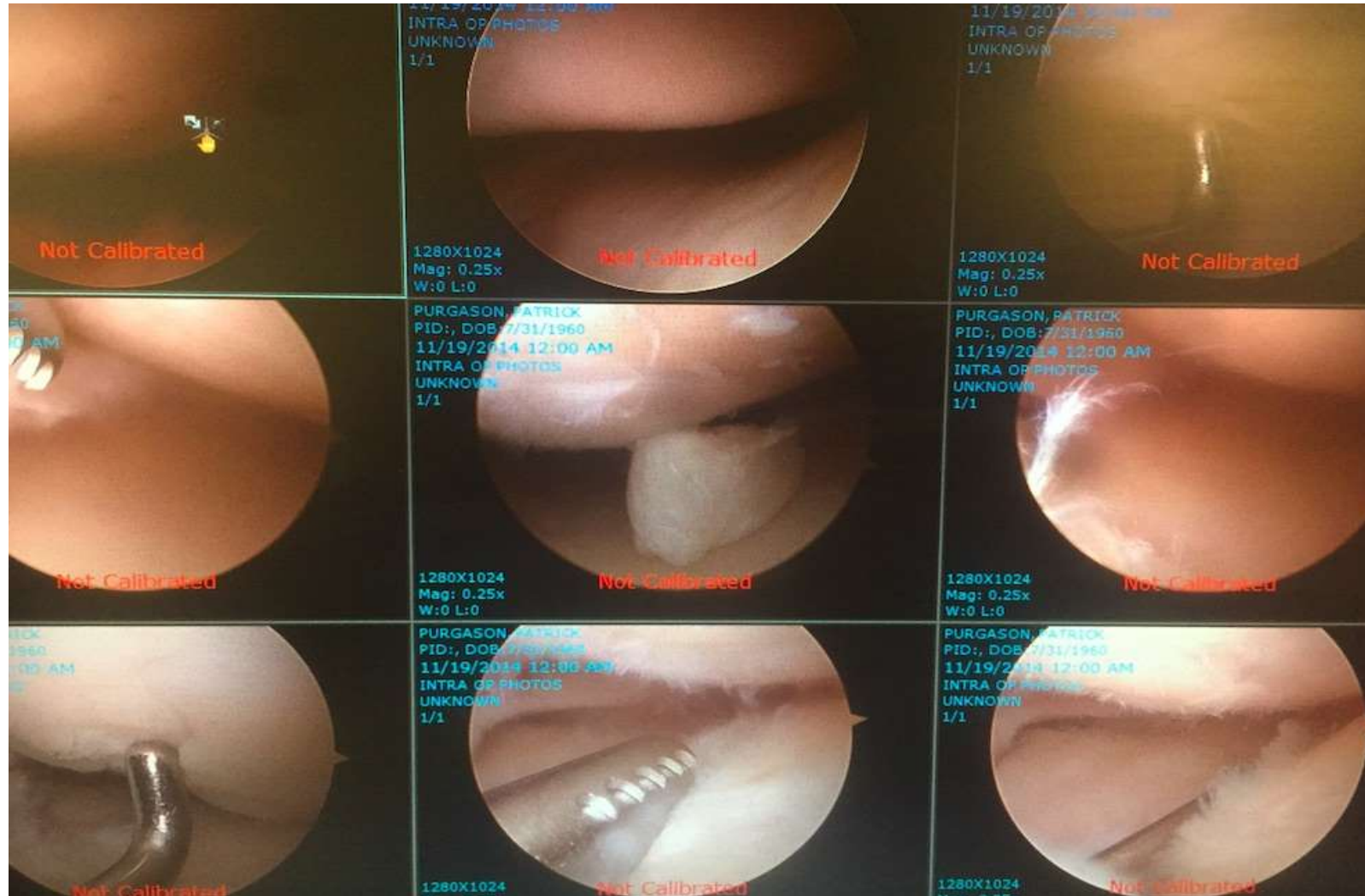BMAC Injection vs ACI

- **Autologous bone marrow-derived mesenchymal stem cells versus autologous chondrocyte implantation: An observational cohort study.** Am J Sports Med 38:1110–1116 Nejadnik et al 2010
 - 72 matched patients followed for 3, 6, 9, 12, 18, 24 months
 - Functional outcomes were equal at **2 years'** follow-up, with less cost and donor site morbidity noted in the BMAC group

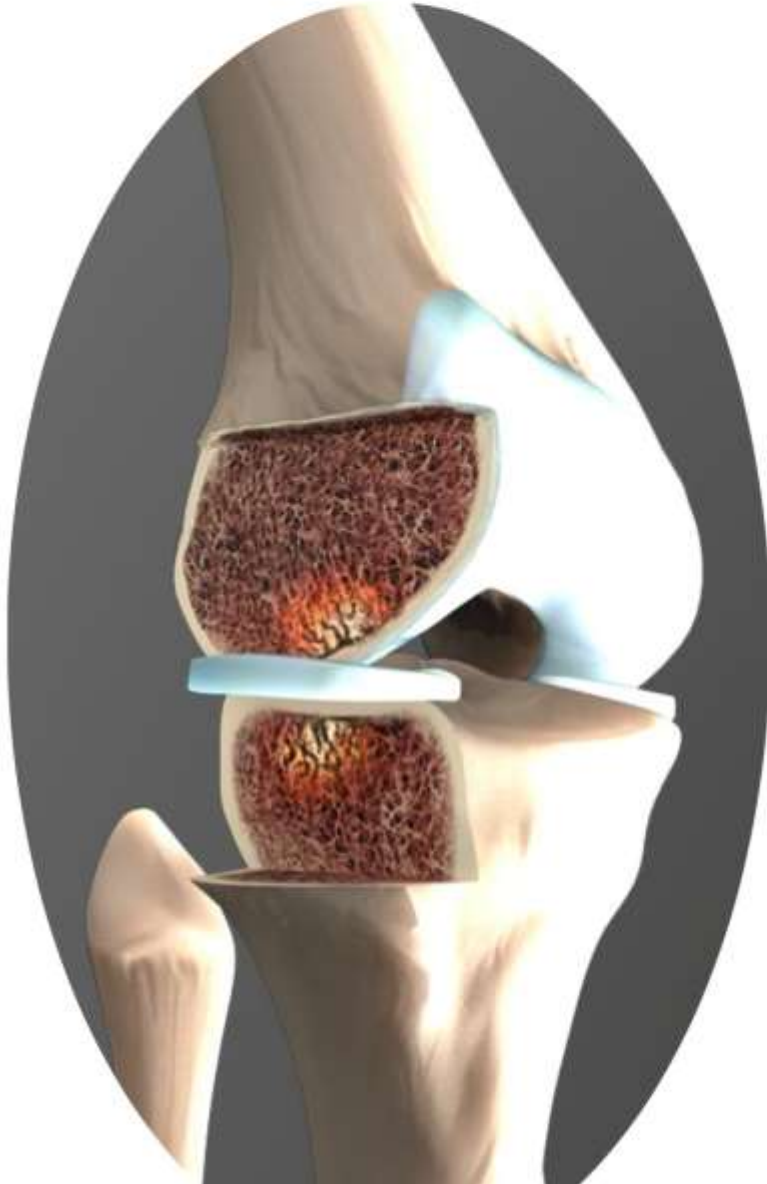
Stem Cell in Knee OA

- **Mesenchymal Stem Cell Implantation in Knee Osteoarthritis: An Assessment of the Factors Influencing Clinical Outcomes.** Kim et al Am J Sports Med. 2015 Jun 25
- **Methods:** Retrospective follow up of 49 pts s/p MSC injection for knee OA
- **Inclusion:** Isolated full-thickness cartilage lesion and Kellgren-Lawrence OA grade 1 or 2
- **Outcomes:** *Excellent (43.6%), 17 as good (30.9%), 11 as fair (20.0%), and 3 as poor (5.5%)*

Arthritis: Role of Arthroscopic Surgery



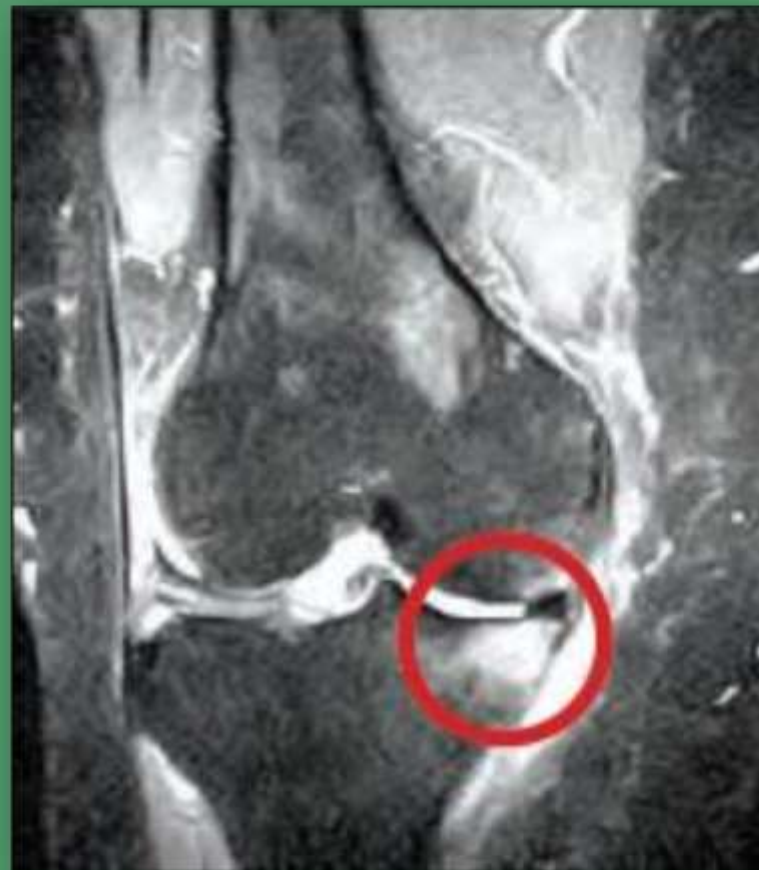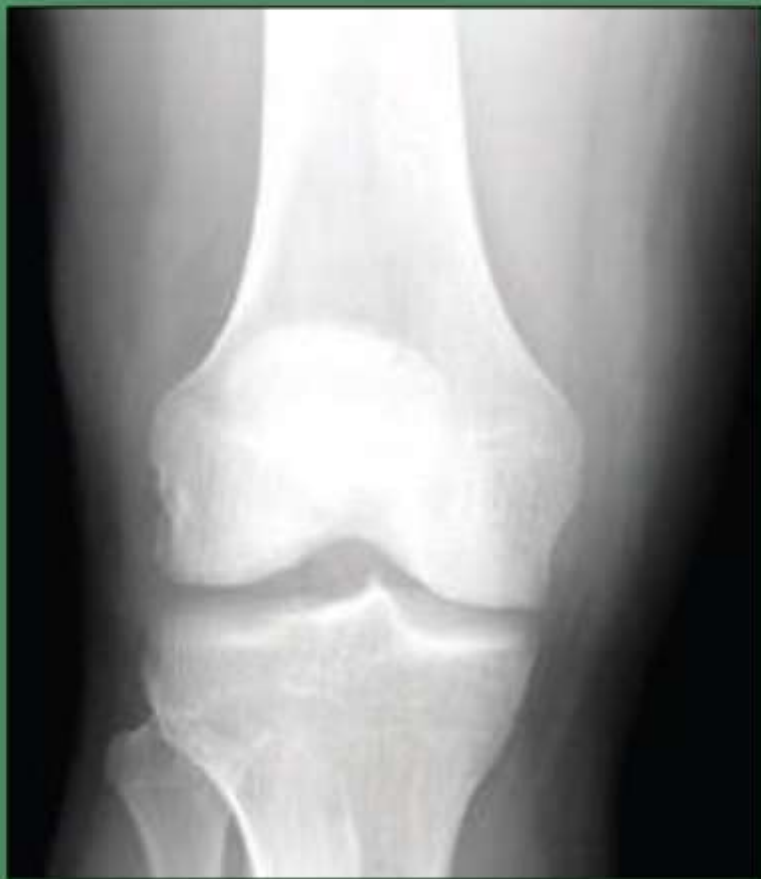What Are Bone Marrow Lesions (BML's)?



BML Characteristics¹:

- Micro-cracks / defects (like a stress fracture)
- Represent a healing response surrounding insufficiency fractures
- Chronic inflammation associated with structurally altered bone
- Often underlies cartilage defect
- Weakened bone at site of defect

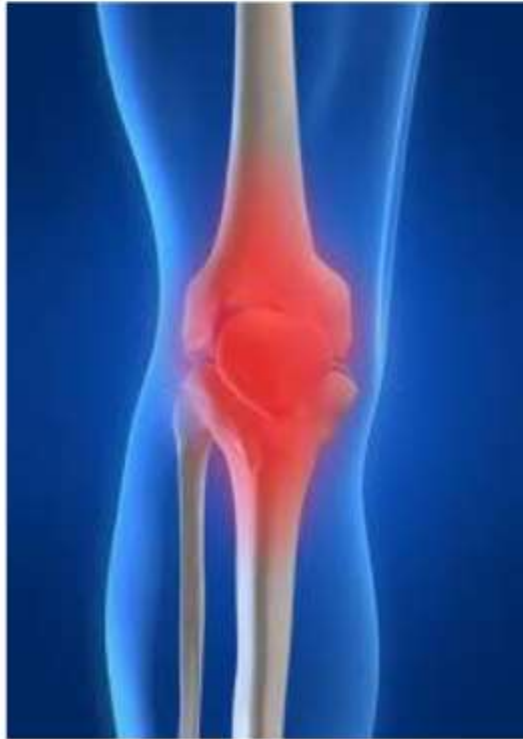The Knee Patient Contradiction



X-Rays Do Not Always Tell The Whole Story

Do You See This MRI Finding? How Do You Treat It?

But Which Factor(s) Cause Pain?



What do We Know?

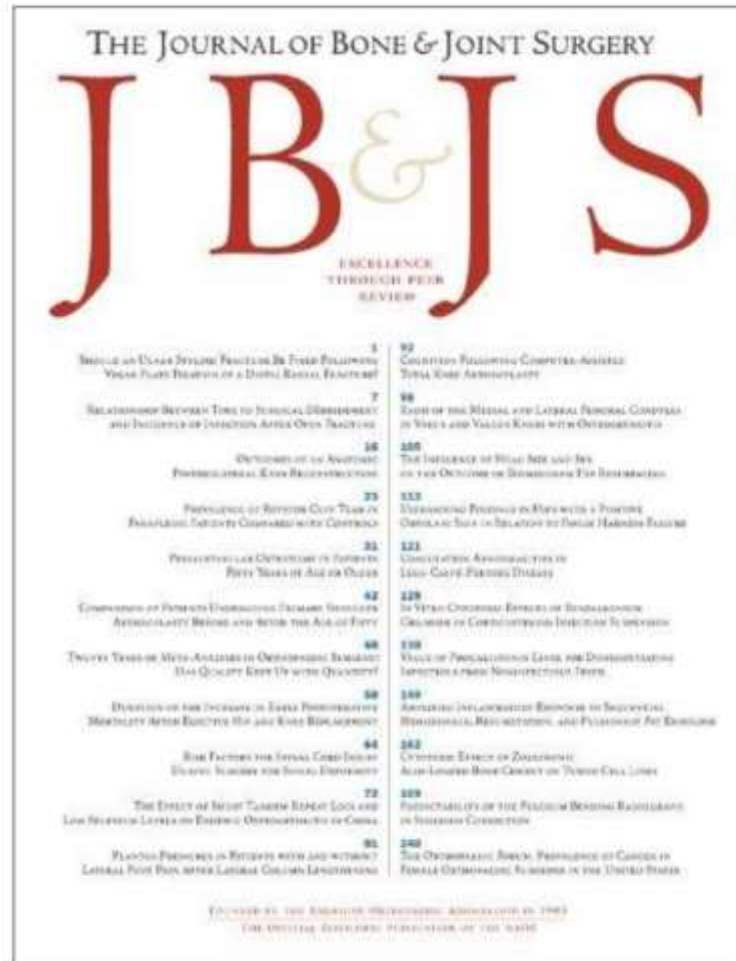- Articular cartilage has no pain fibers
- Synovium has some pain fibers, but more baroreceptors
- Ligaments have more proprioceptors
- Bone has pain fibers

What Does the Literature Say About Knee Pain?

- Strongly related to large Bone Marrow Lesions (BMLs)
- Moderately related to synovitis & effusion
- Weakly related to cartilage volume / thickness

How Do We Know?

In 2011, BMLs were 1st Acknowledged in Mainstream Ortho Lit for their Correlation with the Presence of Pain & Decreased Function

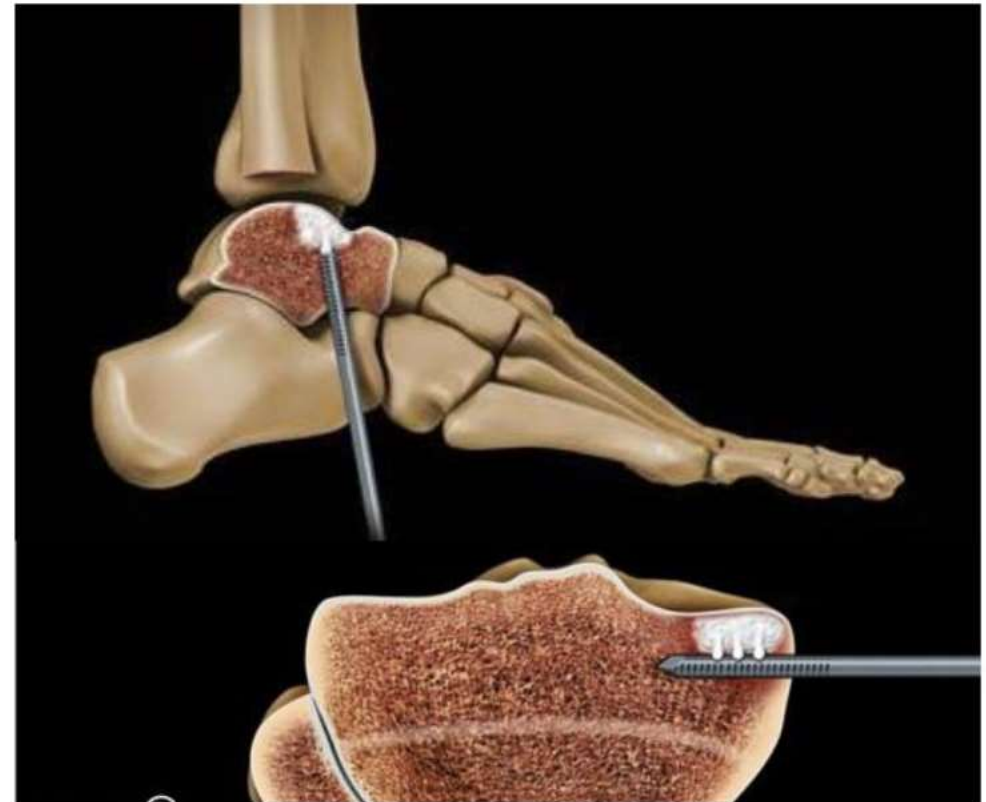

Associations of Anatomical Measures from MRI with Radiographically Defined Knee OA Score, Pain, & Function

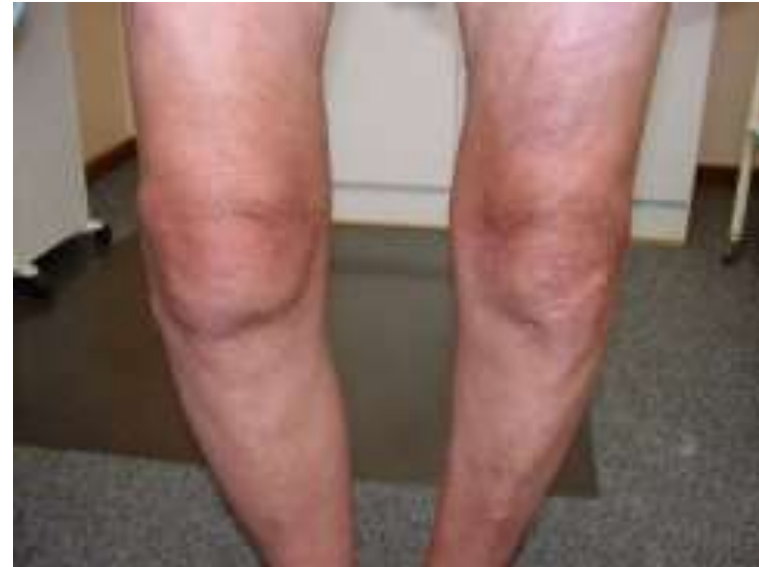- “**Large bone marrow lesions** in the medial femoral condyle or the medial or lateral plateau **were associated with substantially increased odds of reported pain**”
- BML in medial compartments associated with “**marked decreases in walking and stair-climbing performance ($p < 0.001$)**”

What is SCP®?

The **Subchondroplasty®** Procedure (**SCP®**) is a minimally-invasive, fluoroscopically-assisted procedure that targets and treats subchondral bone defects associated with Bone Marrow Lesions (BML) through the delivery of **AccuFill®** Bone Substitute Material (BSM).

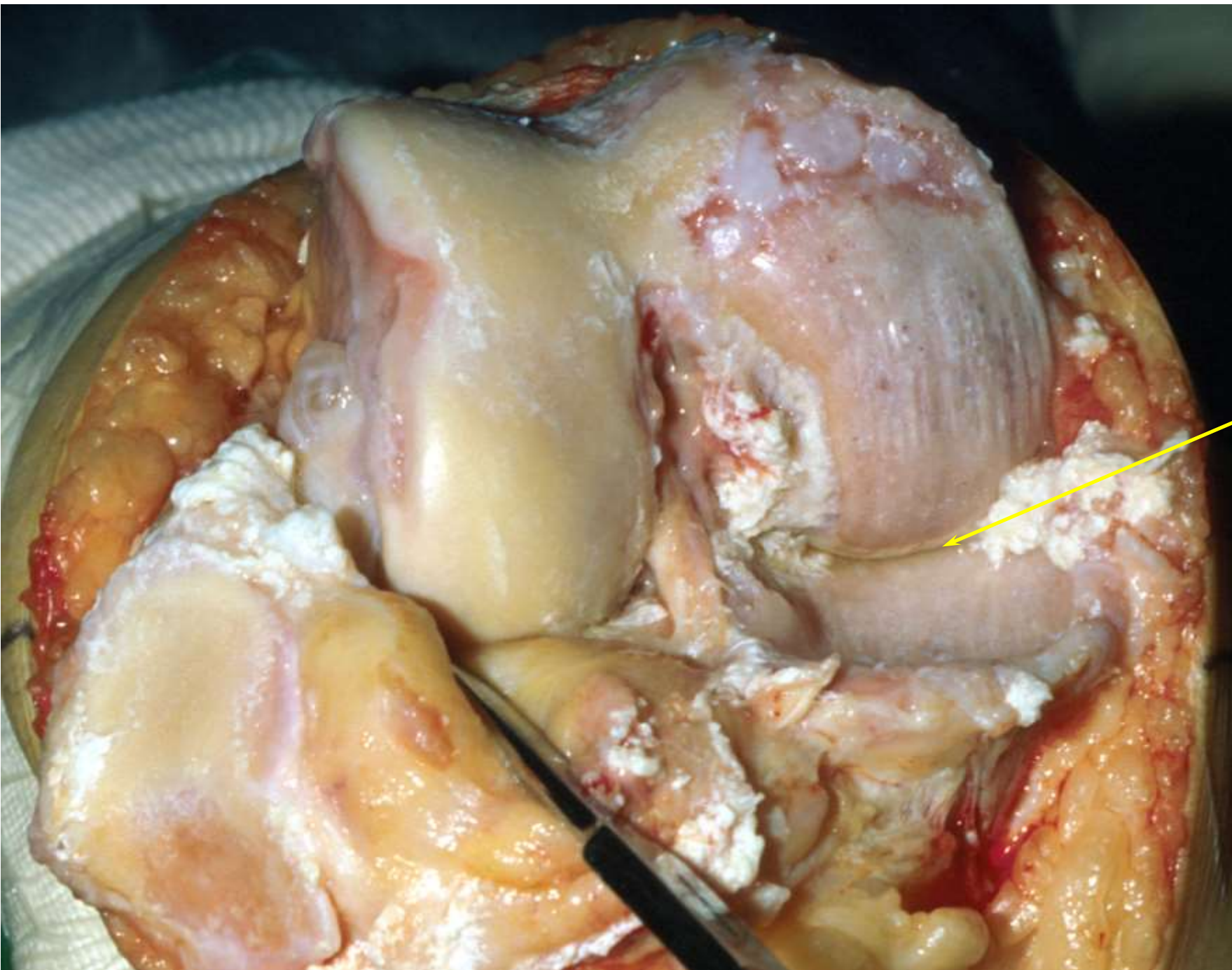


Varus “Bowlegged” Knees

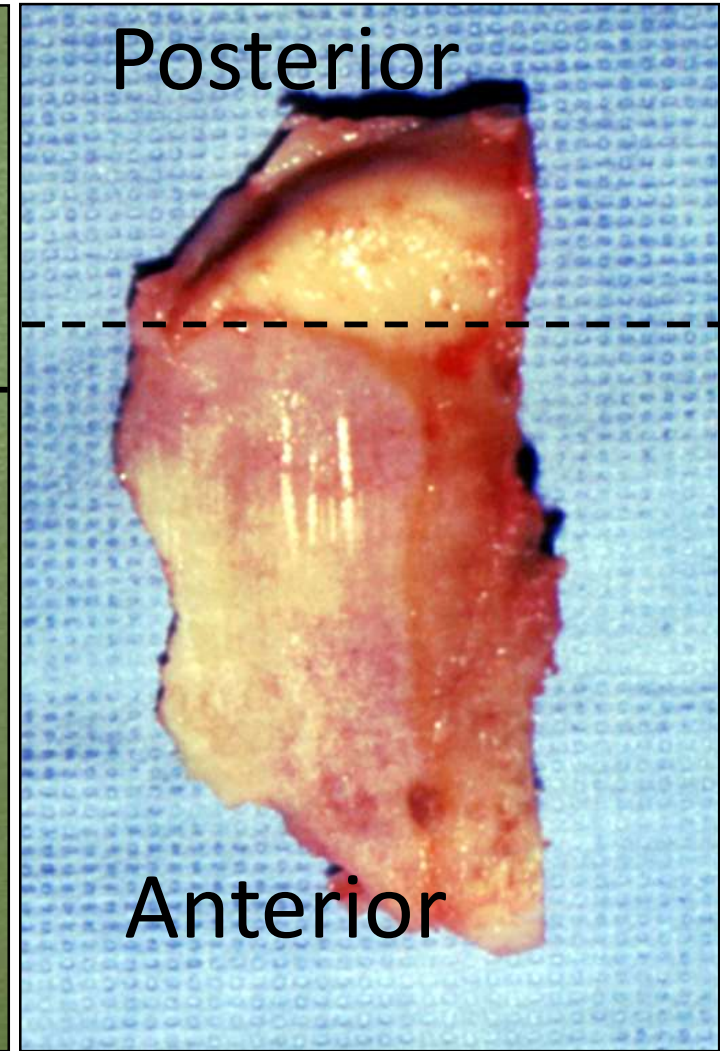

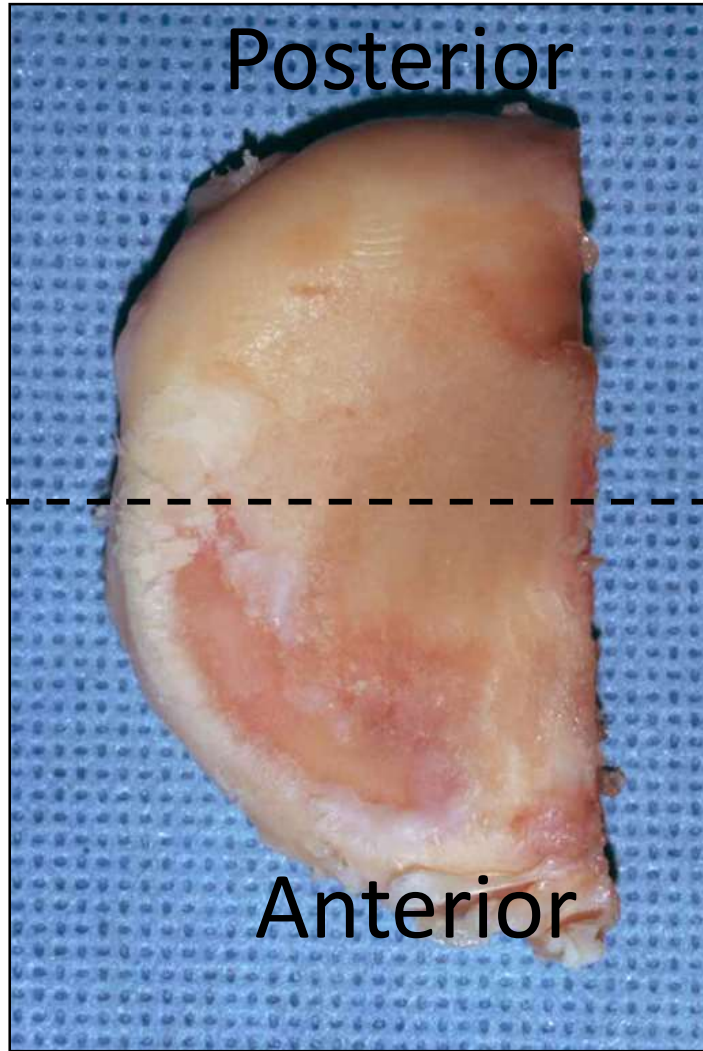


"Anteromedial OA"

- Medial OA
- Preserved posterior cartilage
- Functionally Intact ACL
- Full thickness lateral cartilage

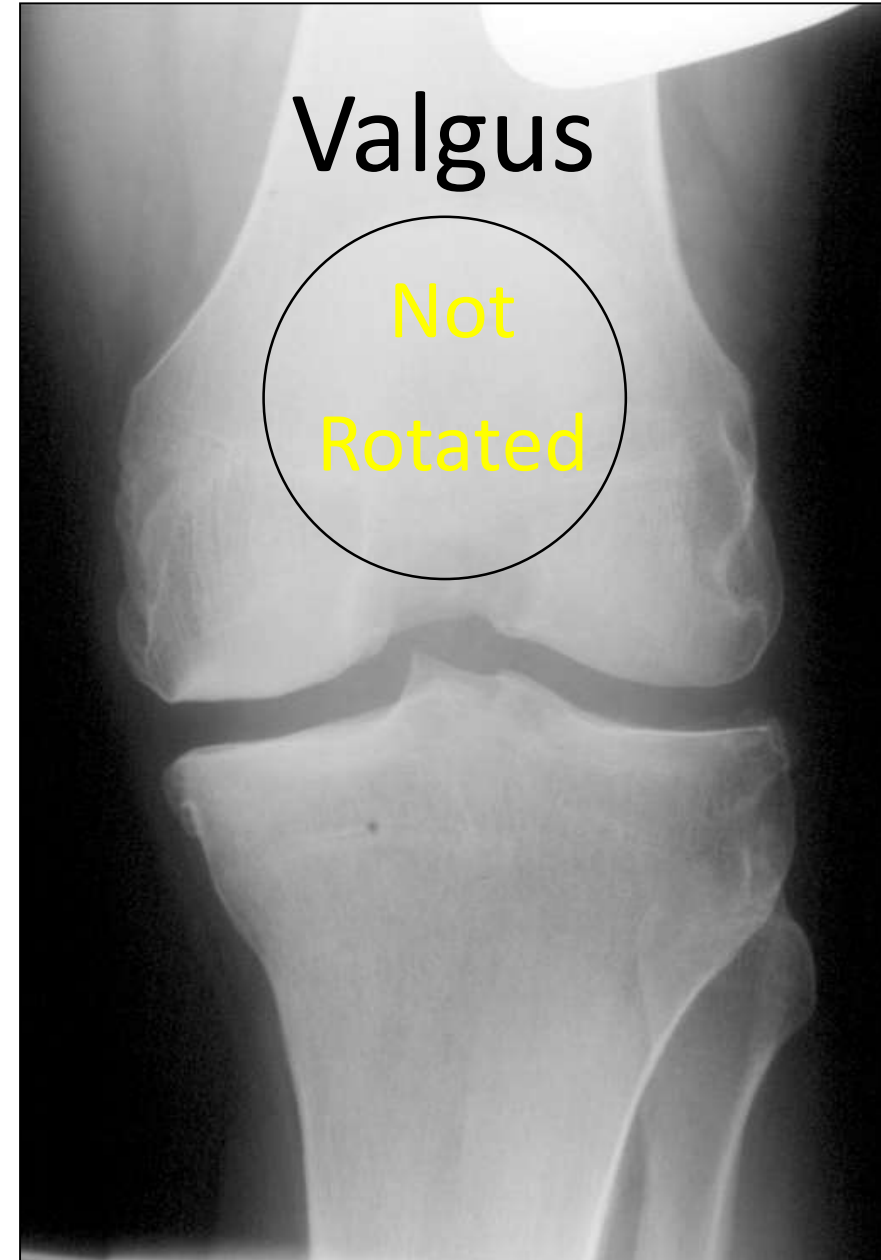
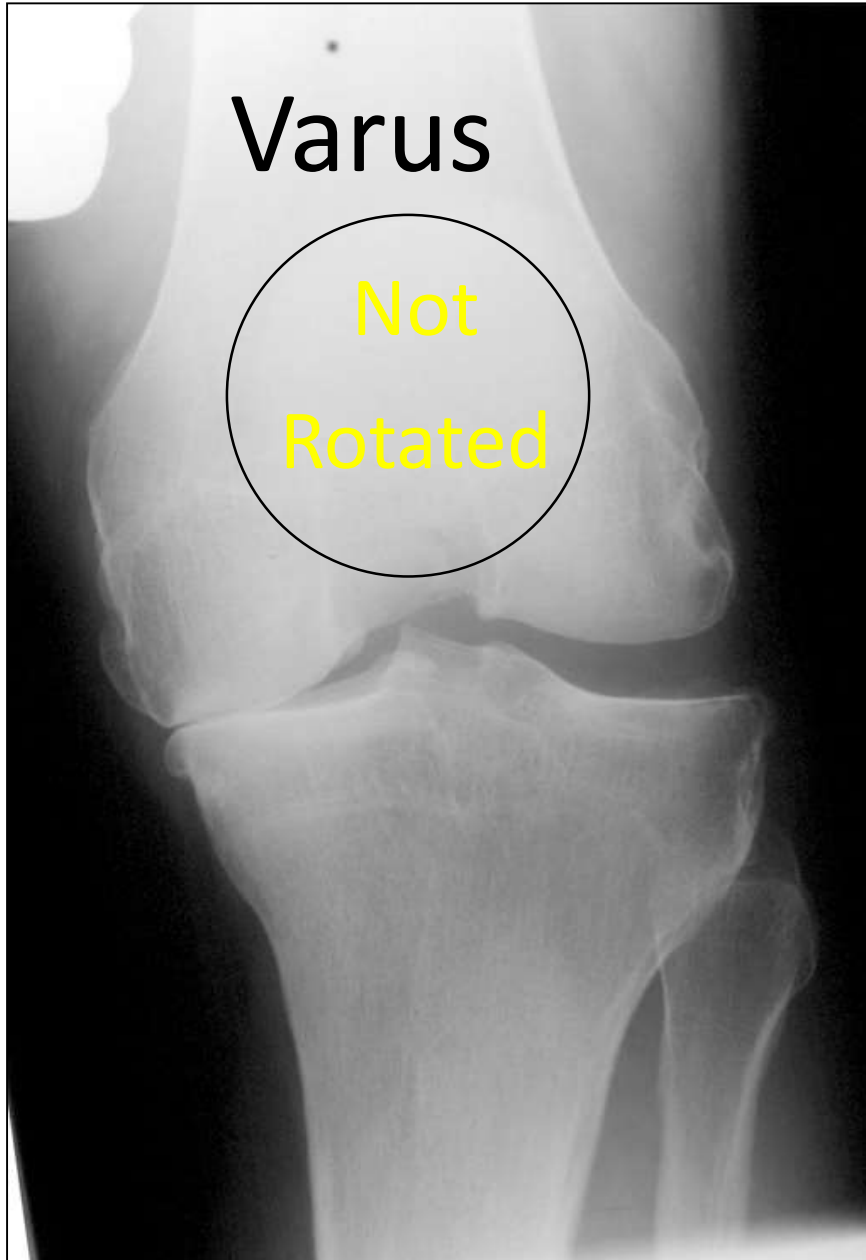

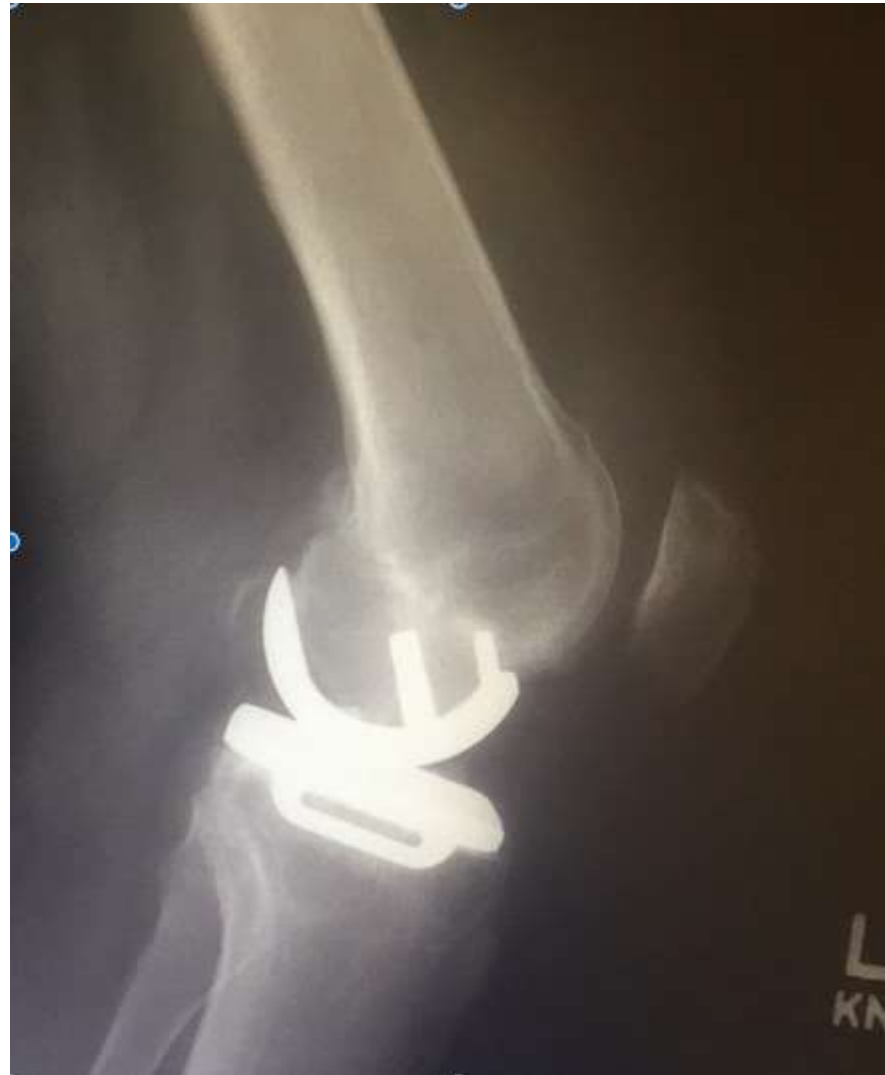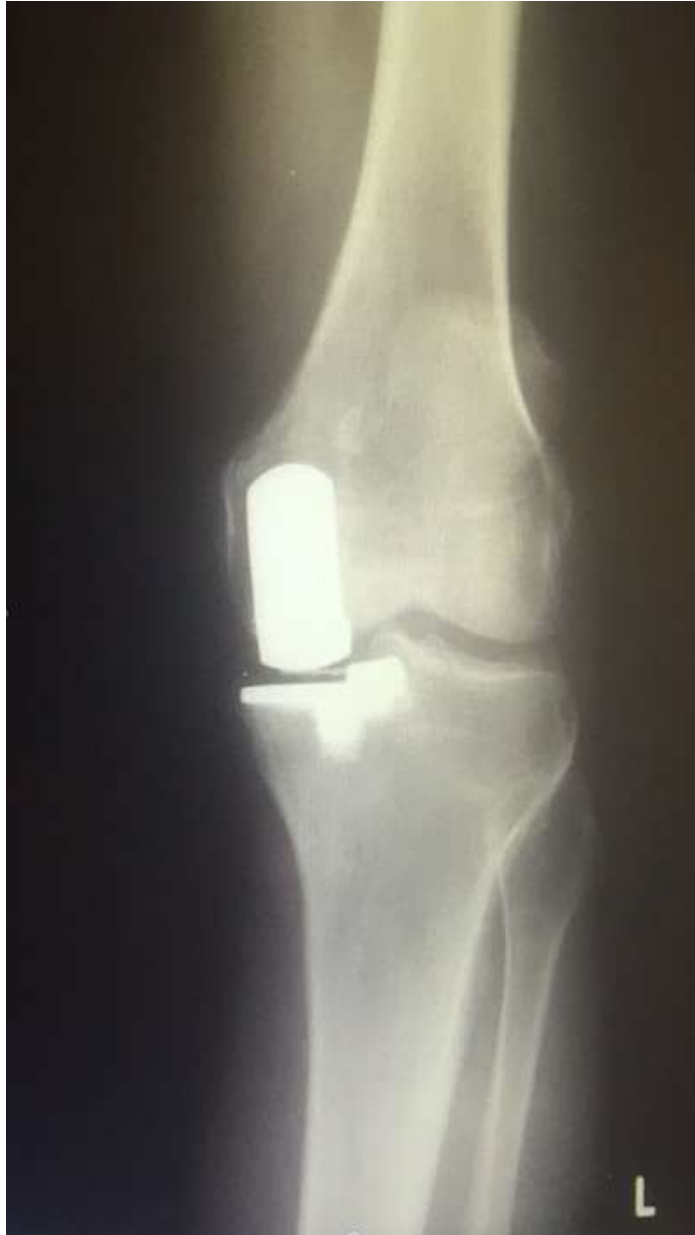AMOA - Typical cases



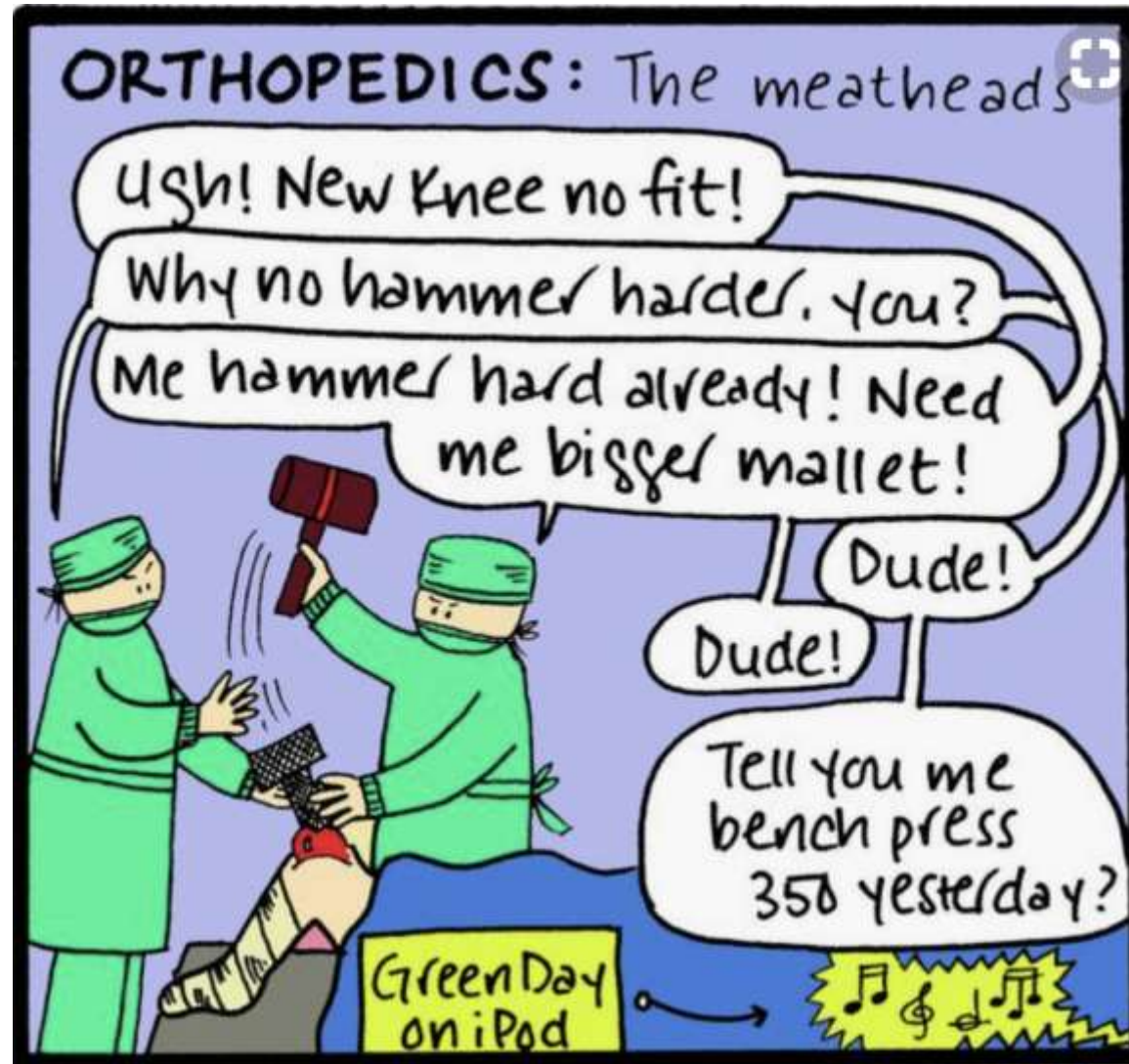
Optimal stress views

- Patella central so not rotated
- Parallel to joint surface
- 20° flexion allows deformity to correct, as posterior capsule short because of FFD





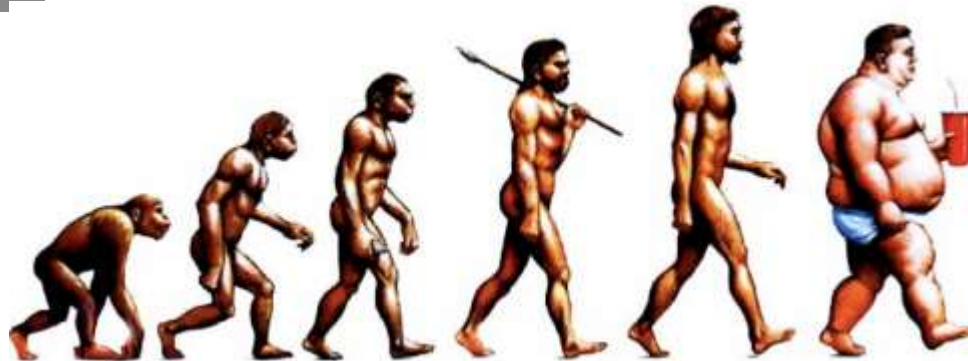
What About Total Knee Replacements?



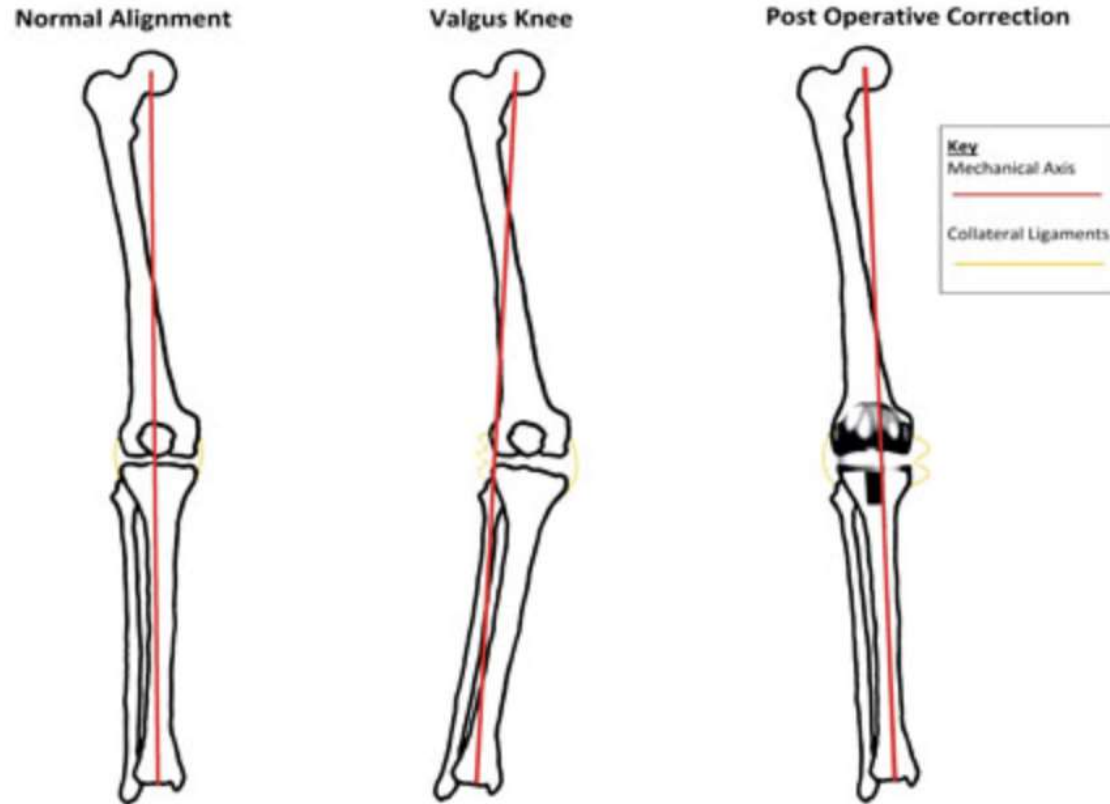
Evolution of Total Knee Arthroplasty (sorry...)



Design
Ideal Alignment
Ligament Balancing
Fixation
Robotics



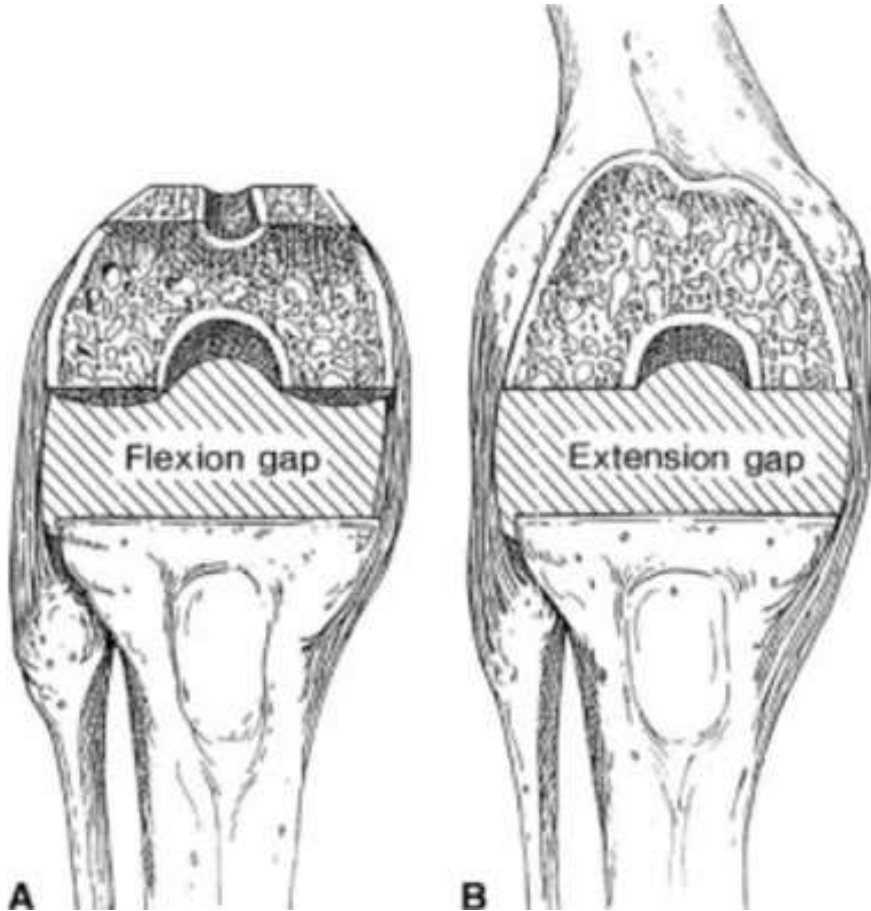
Idealized Limb Alignment (Mechanical Axis)



- “Normal” Average Mechanical Axis 3 degrees varus
 - Men 32% greater than this
 - Women 17%
- Traditional teaching: <3 degrees from Mechanical Axis
- New studies:
 - Improved Functional Scores
 - Longevity Equivalent

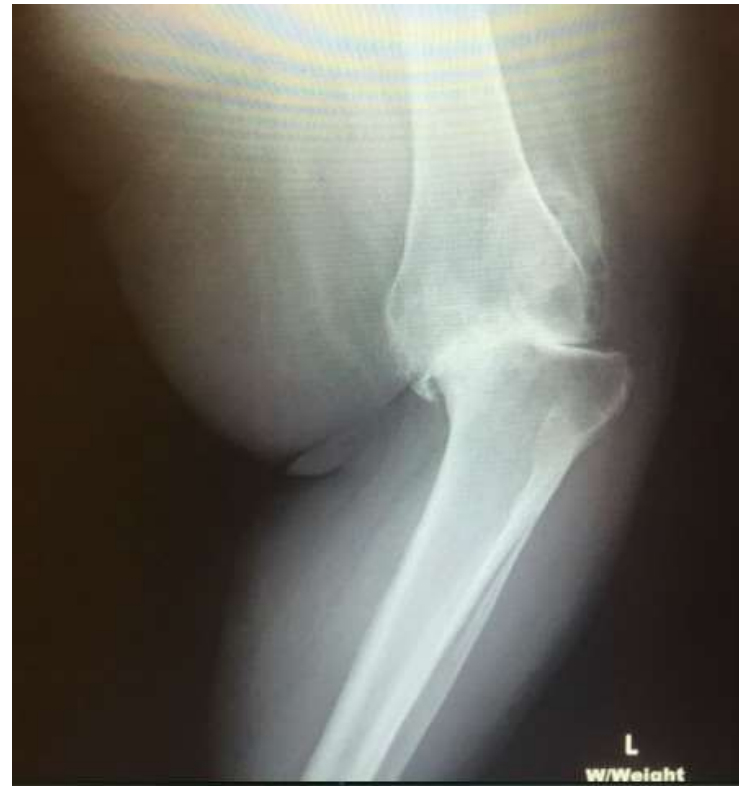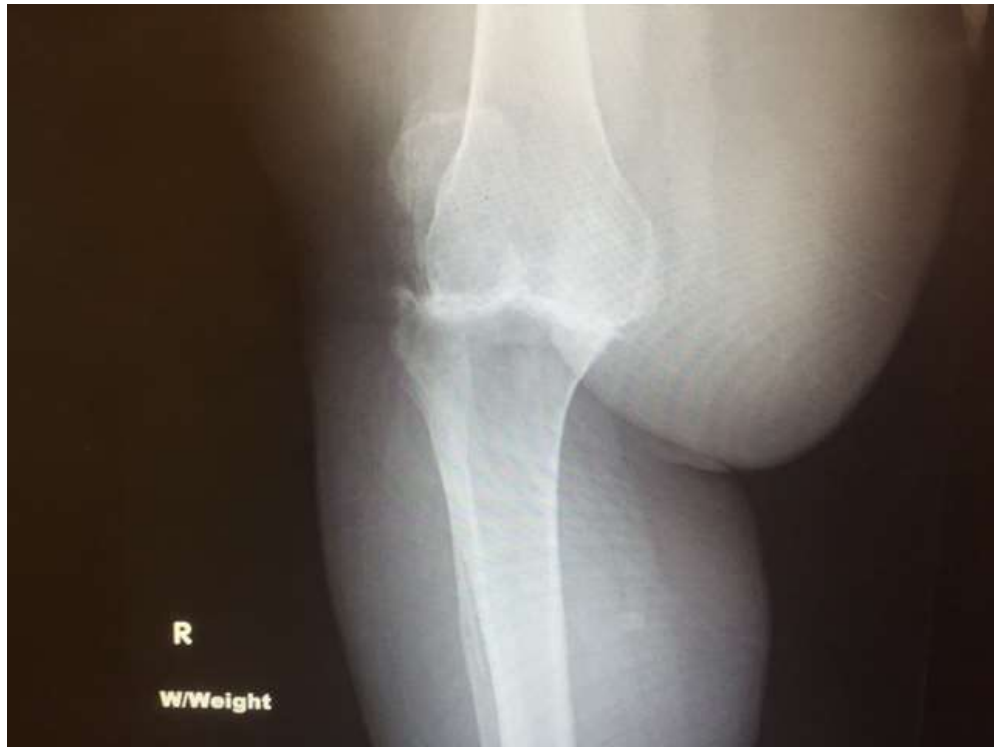Does a kinematically aligned total knee arthroplasty restore function without failure regardless of alignment category? Howell SM, Howell SJ, Kuznik KT, Cohen J, Hull ML *Clin Orthop Relat Res.* 2013 Mar; 471(3):1000-7.

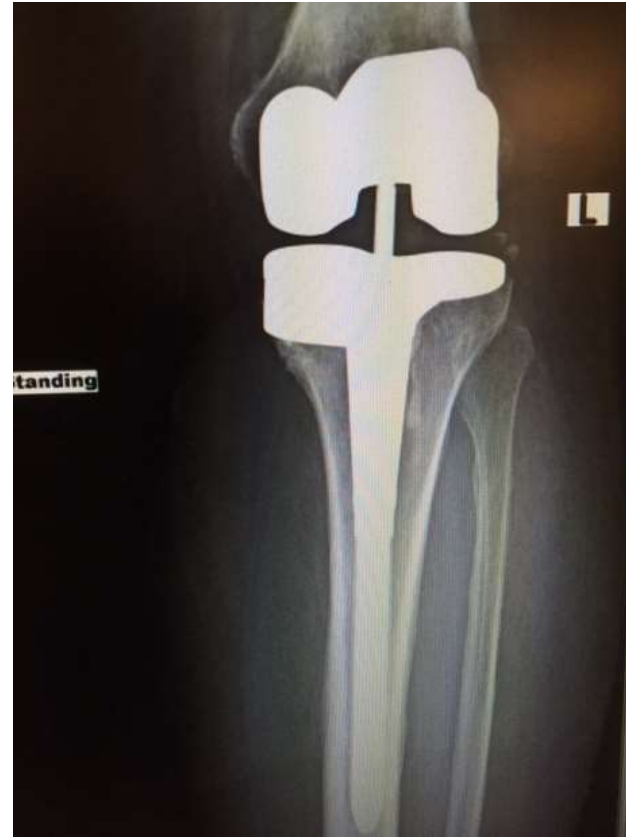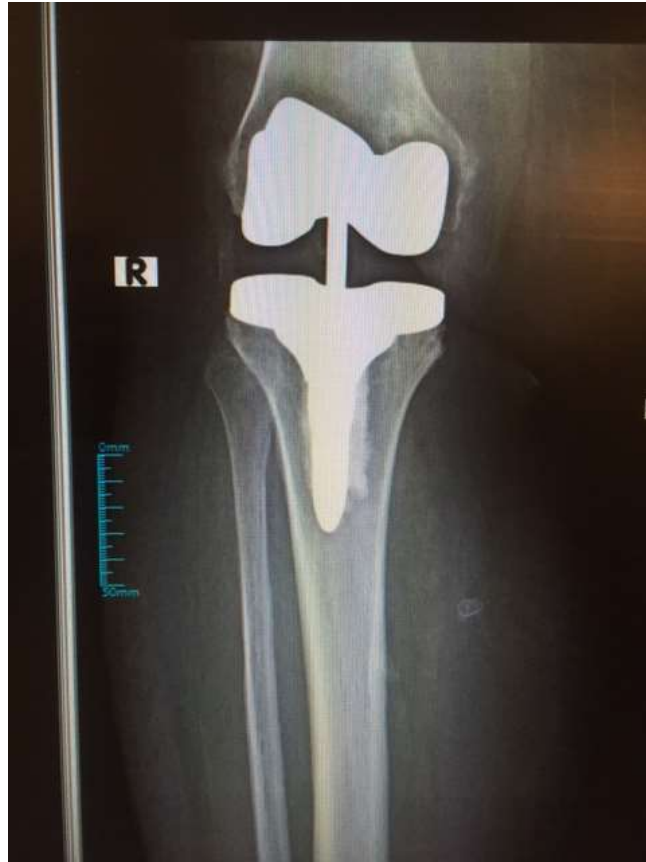Role of Ligamentous Balancing



- Balancing of Flexion and Extension gaps
- Release of ligaments to make the two rectangles equal
- Mid-Flexion instability, Collateral Ligament Stability

What is the role of robotics? This is easy...







This is not...



VS.



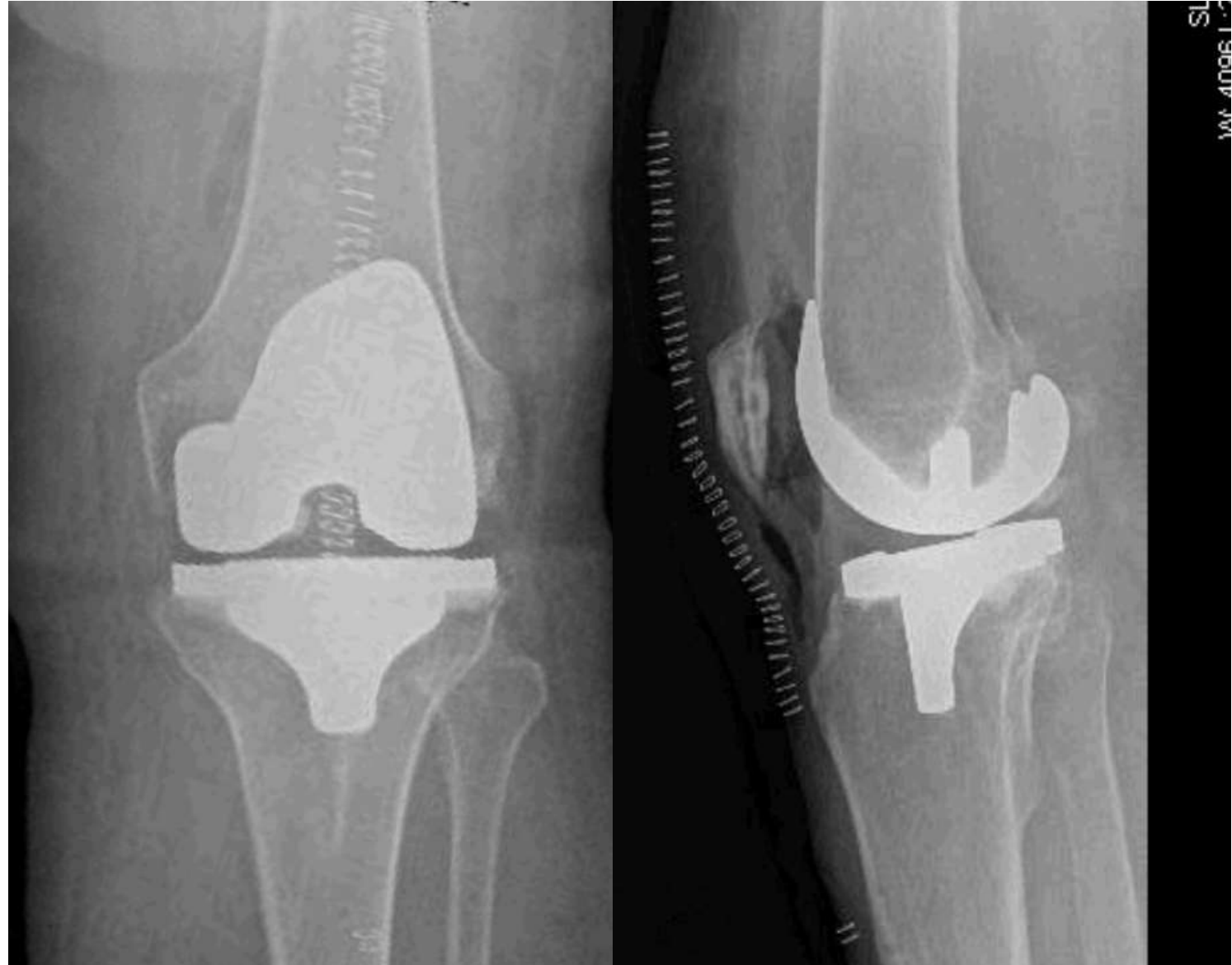
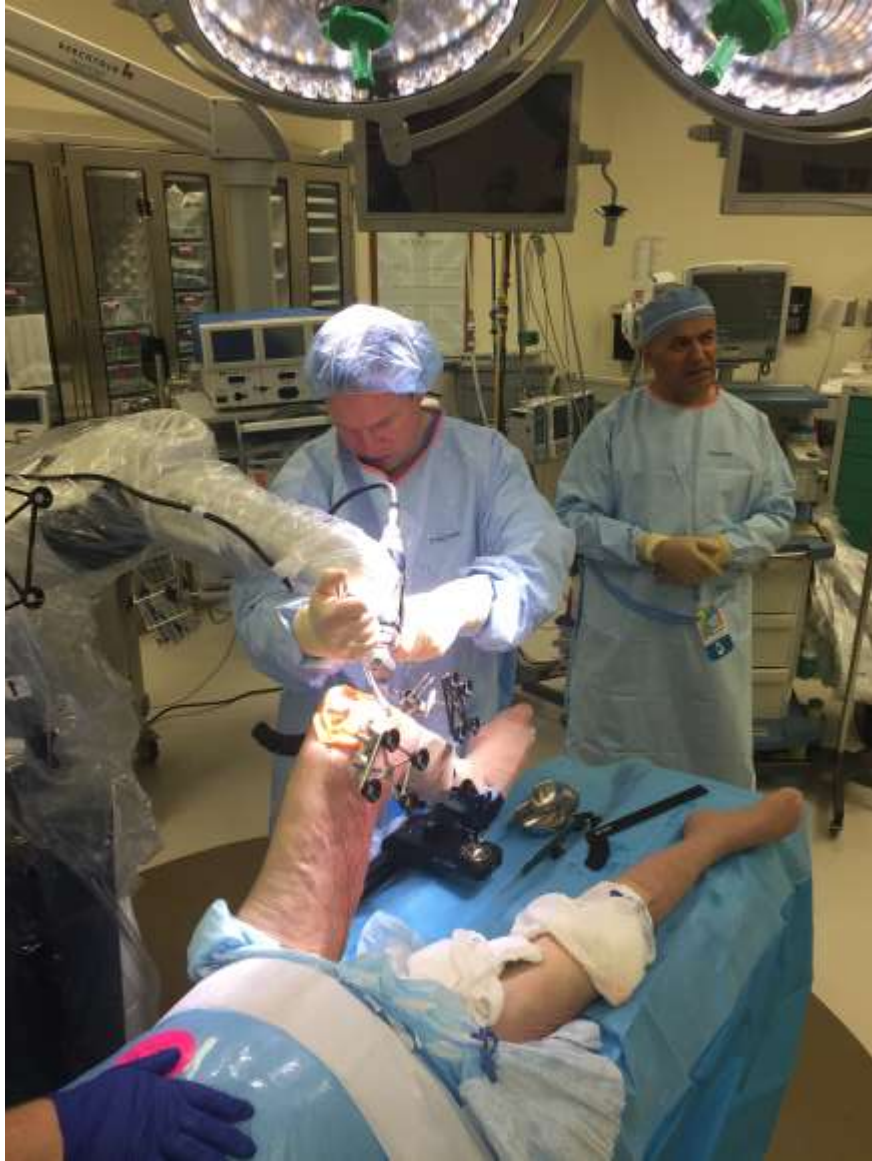Mako Total Knee

- **Enhanced Planning**
- CT based segmentation into a 3D based model of the patient's bony anatomy
- Ability to manipulate the implant in 6 separate degrees of freedom based on key anatomic landmarks

stryker

Treating arthritis with
Mako Total Knee

SVCC Acquires Mako Hip, PK and TKA



Has Mako Robotic Technology Changed my Outcomes?

Manual	Mako	Summaries
162	162	Count n
13.21605	11.42593	Mean
3.092204	2.114151	Standard deviation (variability of individuals)
9	9	Smalles t
11	9	Lower quartile
13	11	Median
16	13	Upper quartile
25	19	Largest
0.242947	0.166103	Standard error

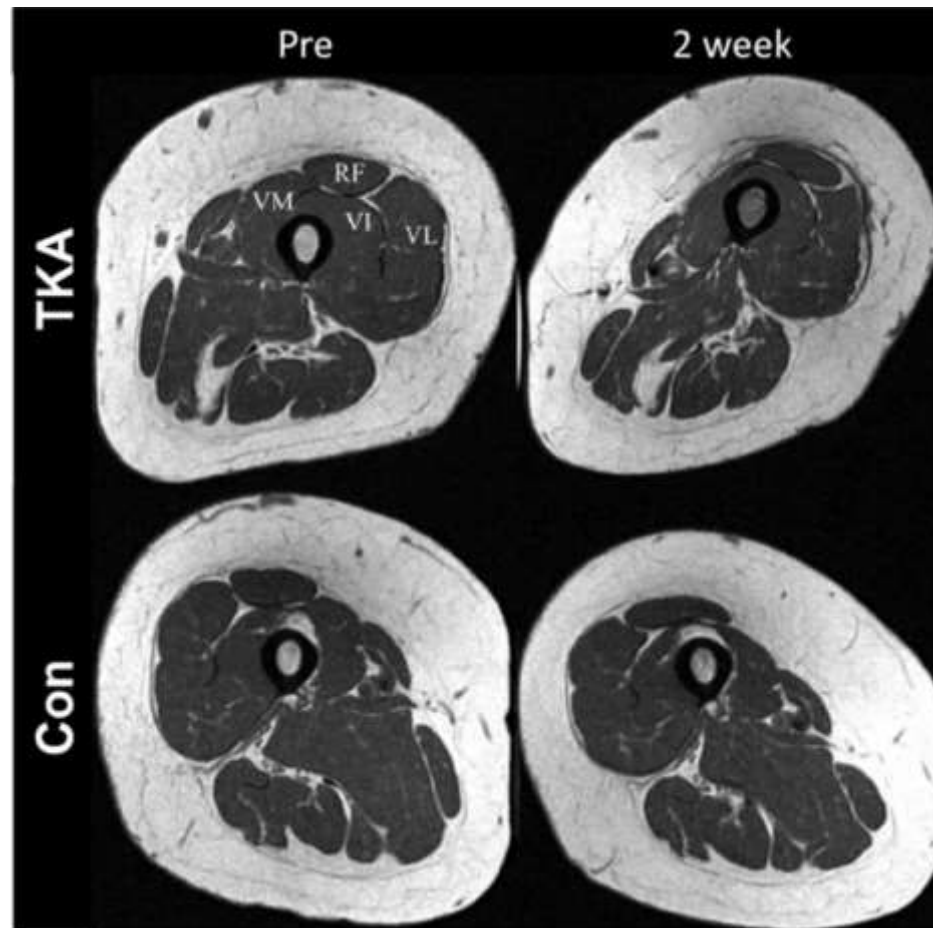
- Cohort of 324 patients (162 in each group)
- Average decrease in flexion and extension gaps 2mm
- Less ligamentous balancing
- Anecdotally, less pain, faster recovery by most

Respect The Quadriceps- No Tourniquet



Higher Blood Loss
Long Term Quadriceps Atrophy
Higher DVT
No difference in cement interdigitation

Cross Section of Thigh Two Weeks after Tourniquet Use in TKA



In conclusion...

- Knee osteoarthritis is many things
- Treatments can be optimized at each stage of the disease
- New technologies improve patient outcomes
- No one size fits all approach!

Thankyou

- Max Lincoln